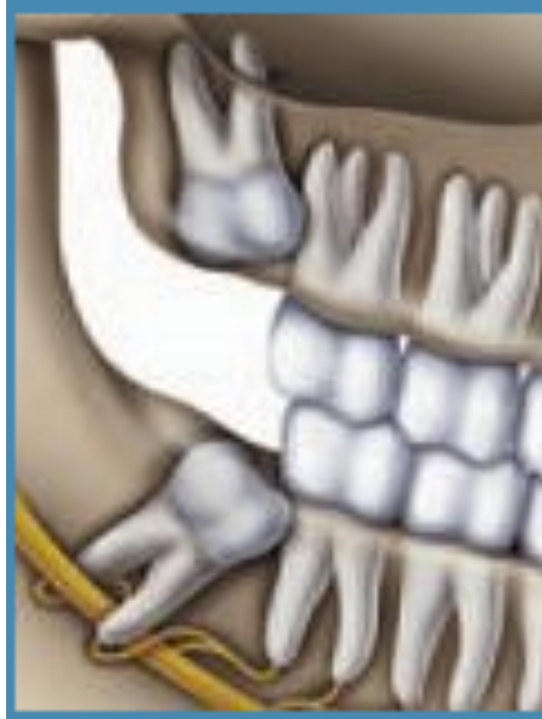



Evidence-Based Management of Third Molar Teeth

Disclaimer

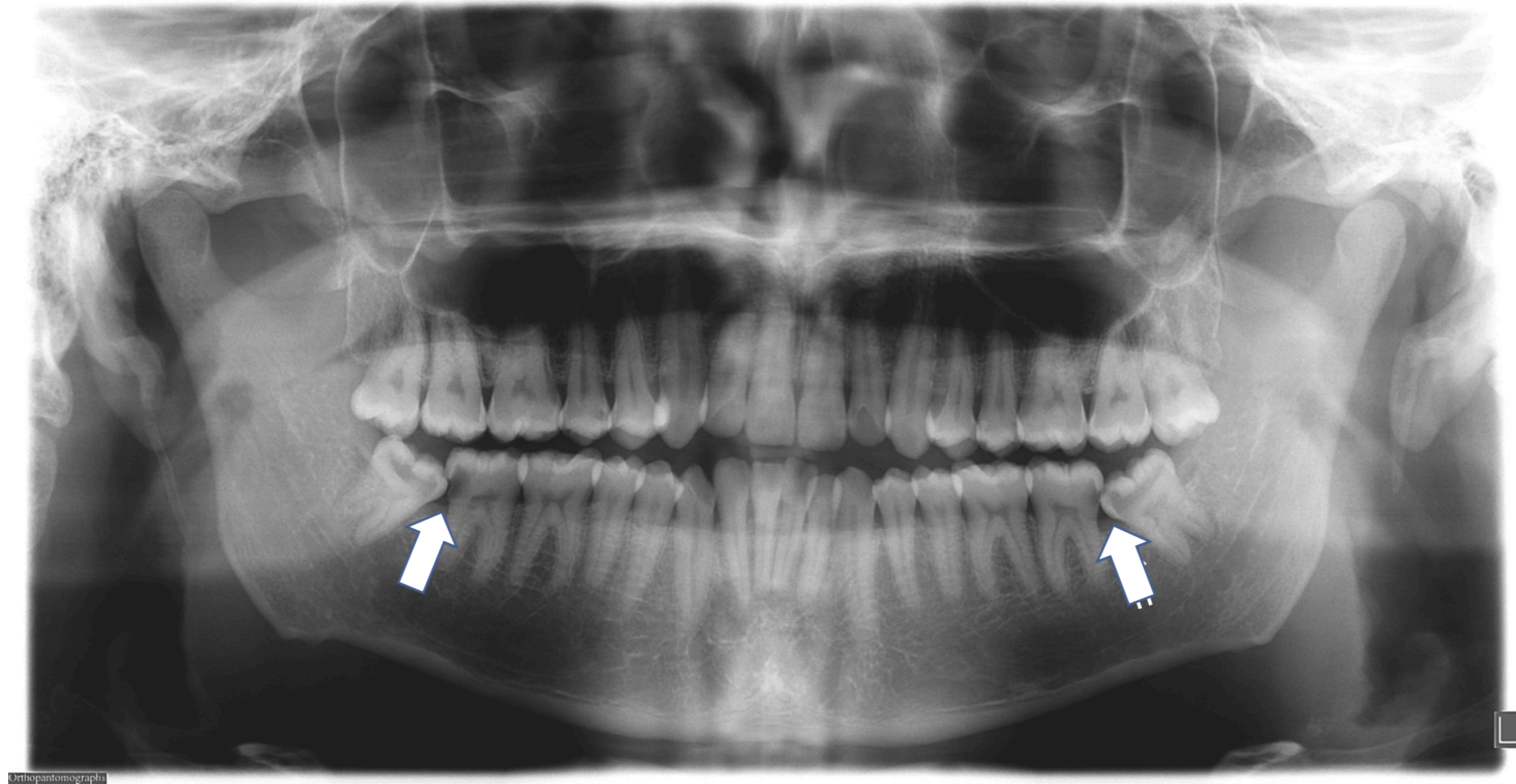
The information depicted in this slide presentation is intended for educational purposes only to help health care professionals better understand the evidence-based management and treatment of third molar teeth. It is not meant as professional advice as all therapeutic decisions remain the responsibility of individual practitioners. The opinions expressed and statements made on this Evidence-based Third Molar PowerPoint Presentation are those of the presenters and do not imply endorsements by or official policy of the AAOMS unless specifically stated otherwise. AAOMS makes no representation or warranty with respect to the material contained within. As with all clinical materials, these slides reflect the science at the time of their development. They should be used with the clear understanding that continued research and practice may result in new knowledge or recommendations. They are not intended to set any standards of care, and they cannot be substituted for individual professional judgment brought to each clinical situation. For assistance concerning the use of this presentation and development of any personal disclaimers to accompany this presentation, fellows and members need to consult their own attorneys locally.

Impacted third molars

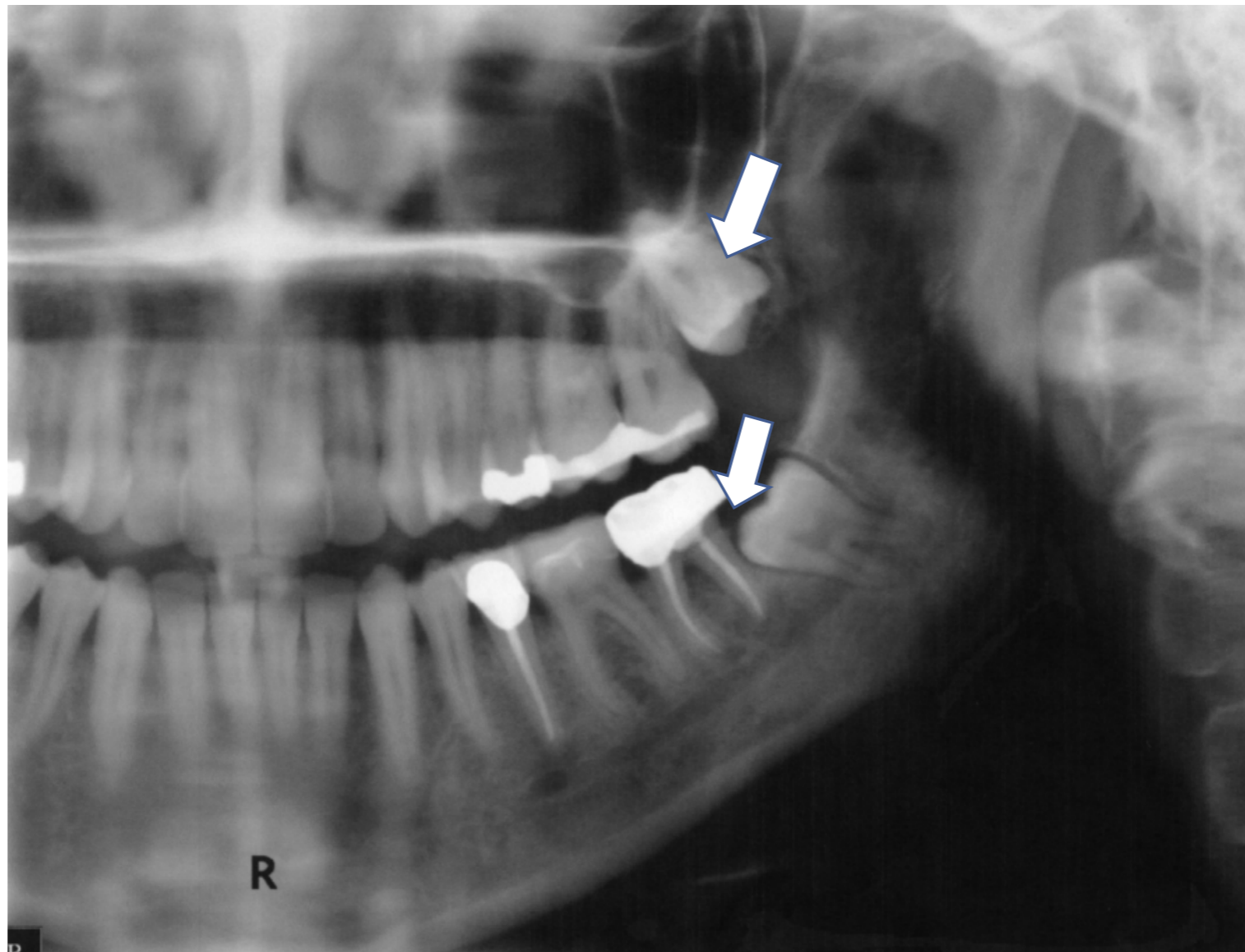
Wisdom teeth, or third molars, are located at the back of the mouth. They are the last adult teeth to erupt, or enter the mouth. Most people have four wisdom teeth, two on the top, two on the bottom.

Third molars are considered to be “impacted” when they don't have enough room to emerge or grow normally.

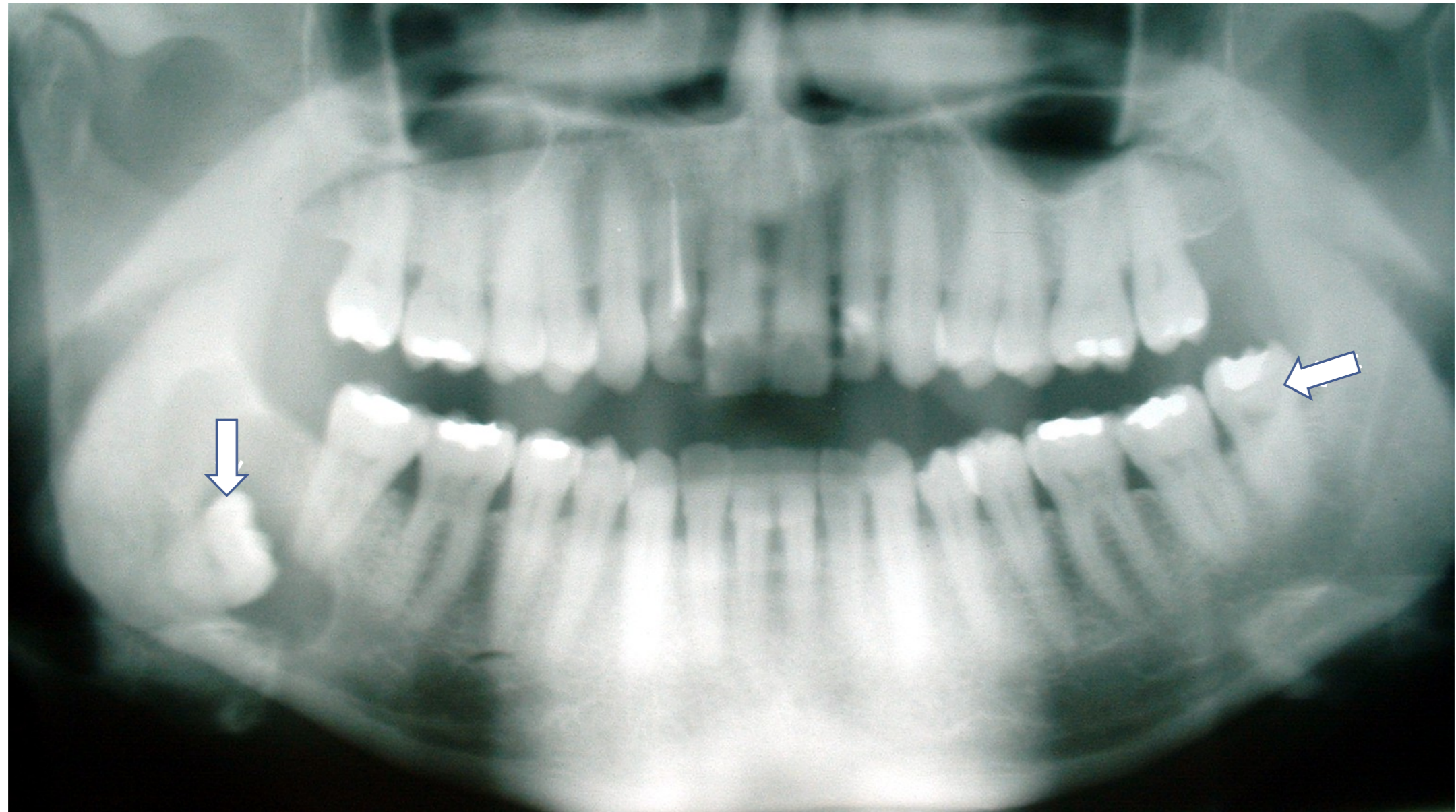
Examples of impacted third molars



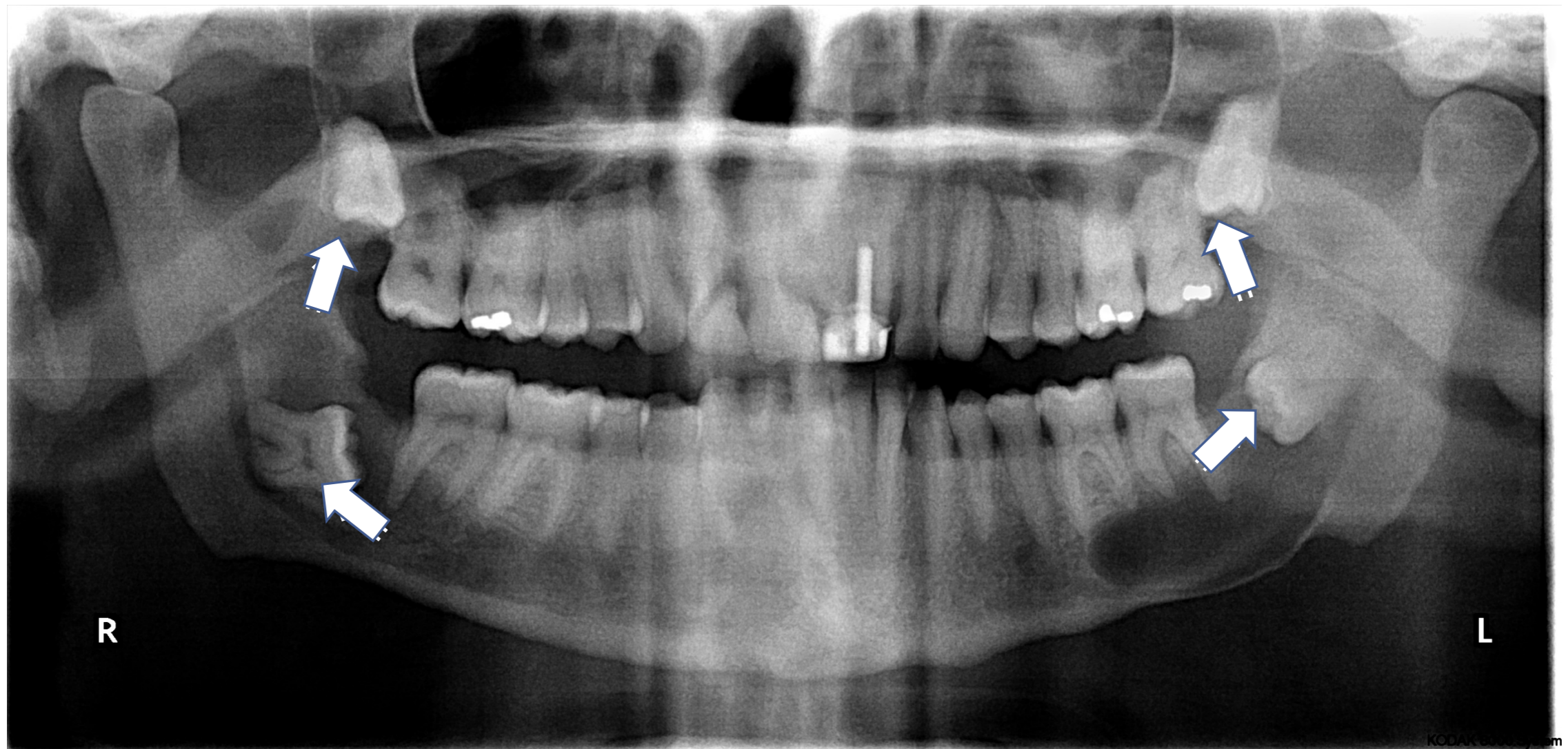
Examples of impacted third molars



Examples of impacted third molars

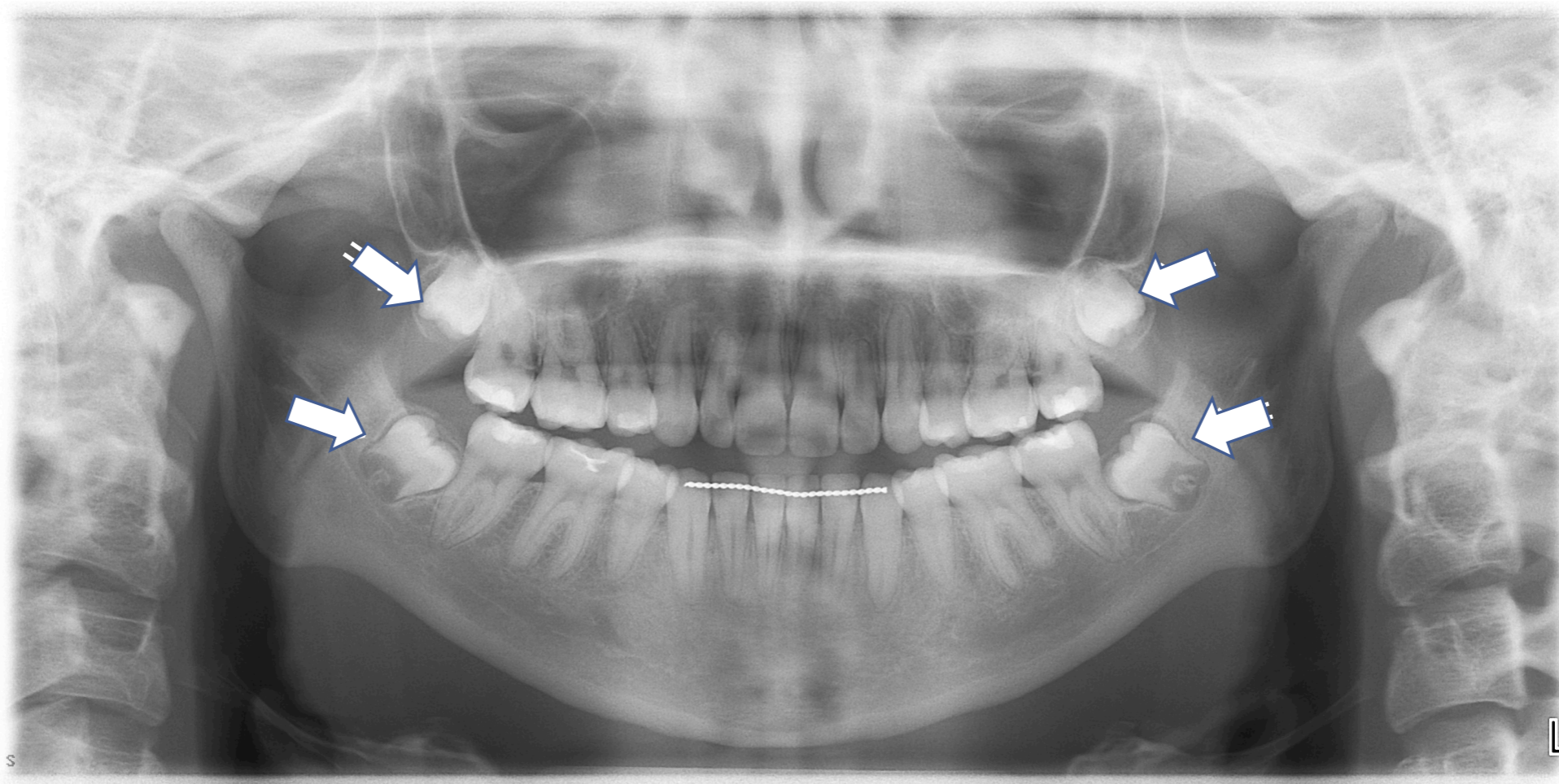


Examples of impacted third molars



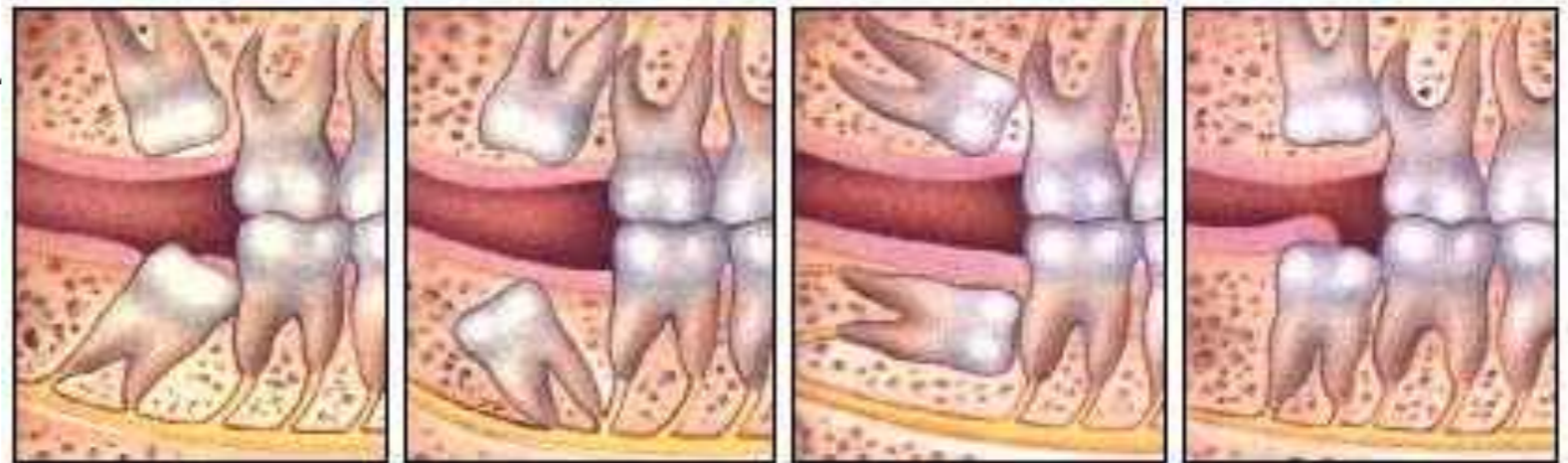Examples of a common dilemma

16-year-old female with 4 asymptomatic and unerupted M3s.



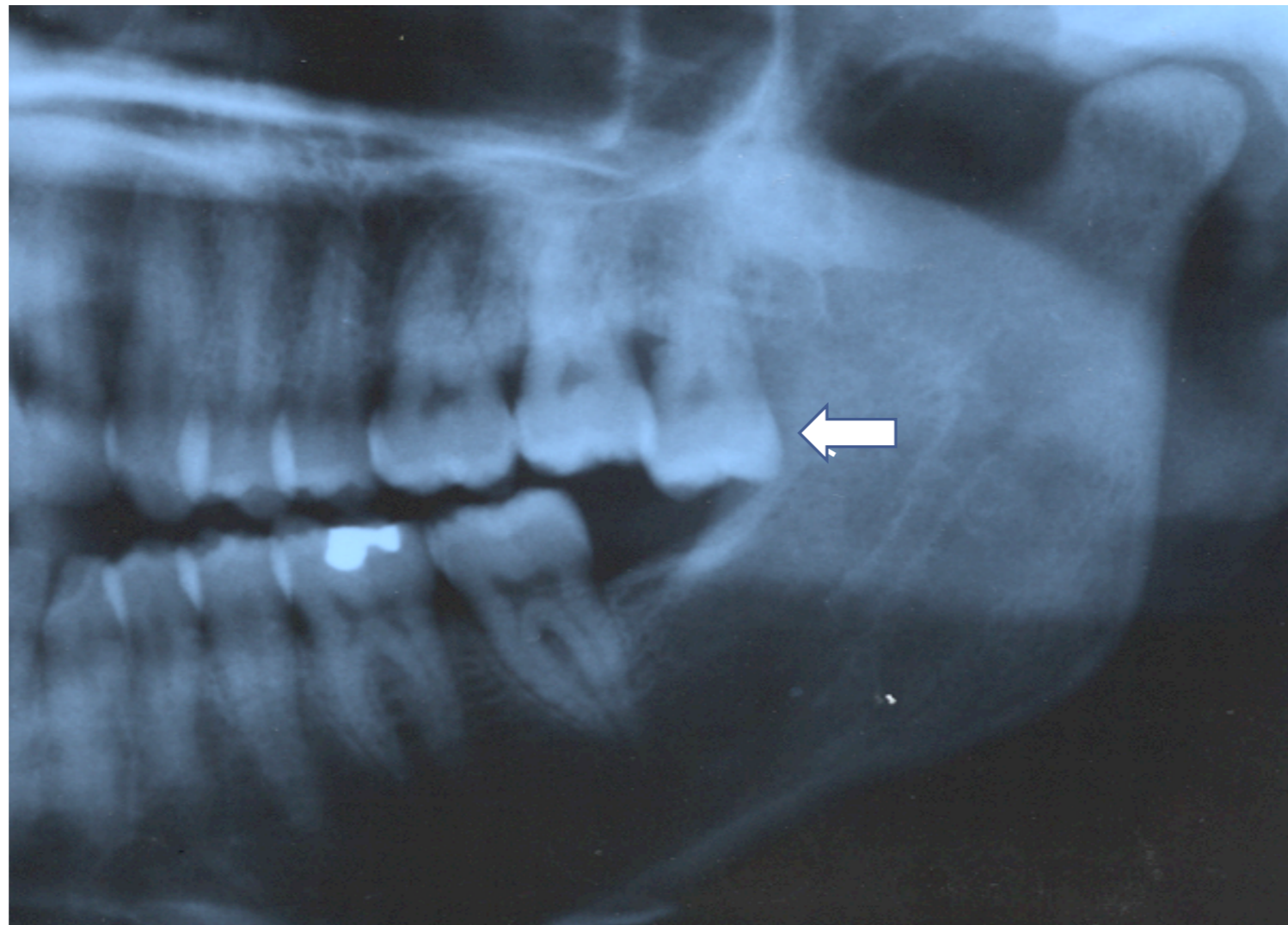
Problems associated with impacted third molars

- Infection,
- Damage to neighboring teeth and tissues,
- Tooth decay,
- Periodontal disease,
- Receding gums,
- Loosened teeth,
- Bone loss,
- Tooth loss,
- Jaw weakening,
- Development of associated cysts and tumors, and
- Interference with needed dental treatments.



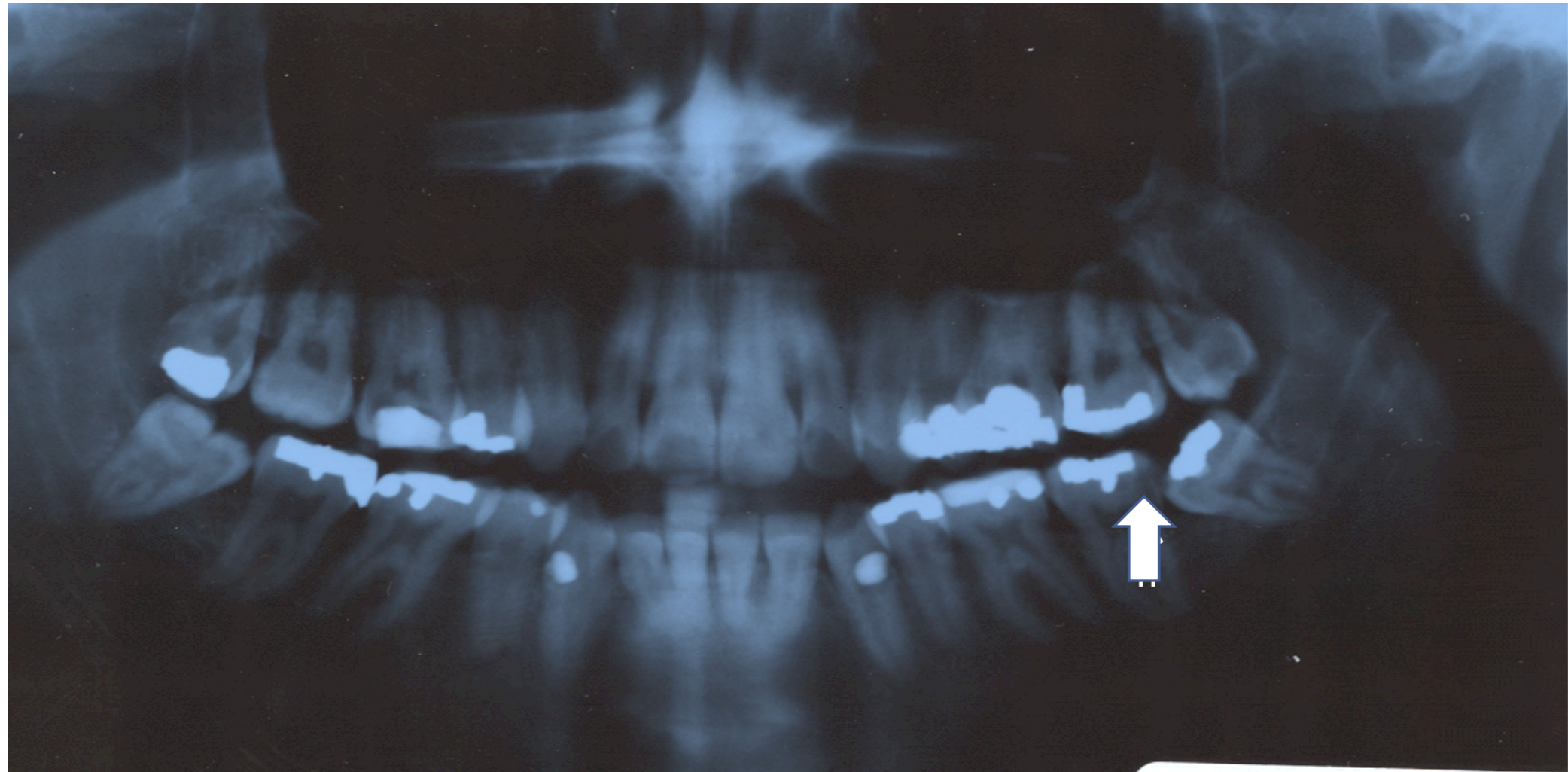
Problems associated with malpositioned third molars

Ectopic positioning due to supra-eruption:



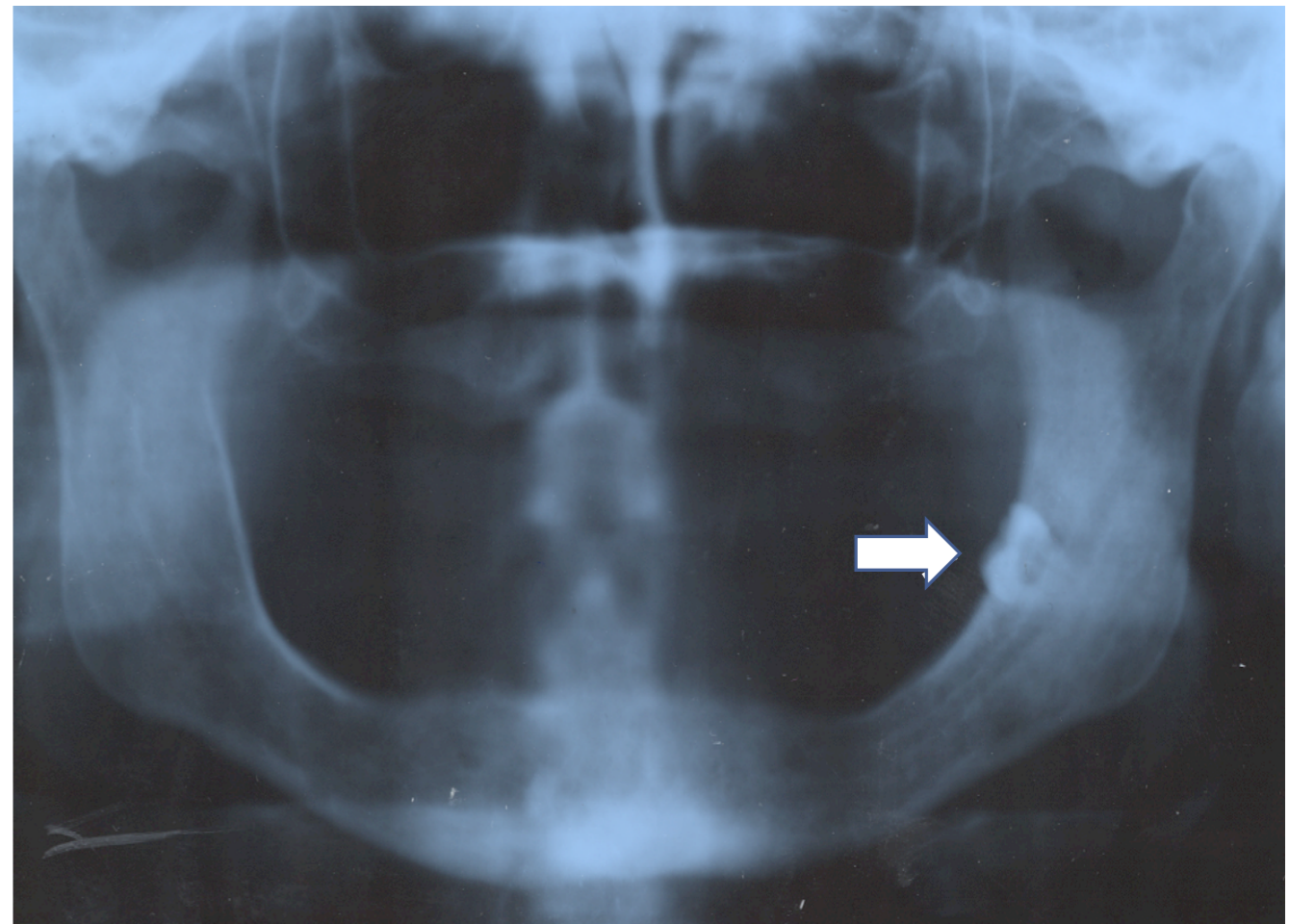
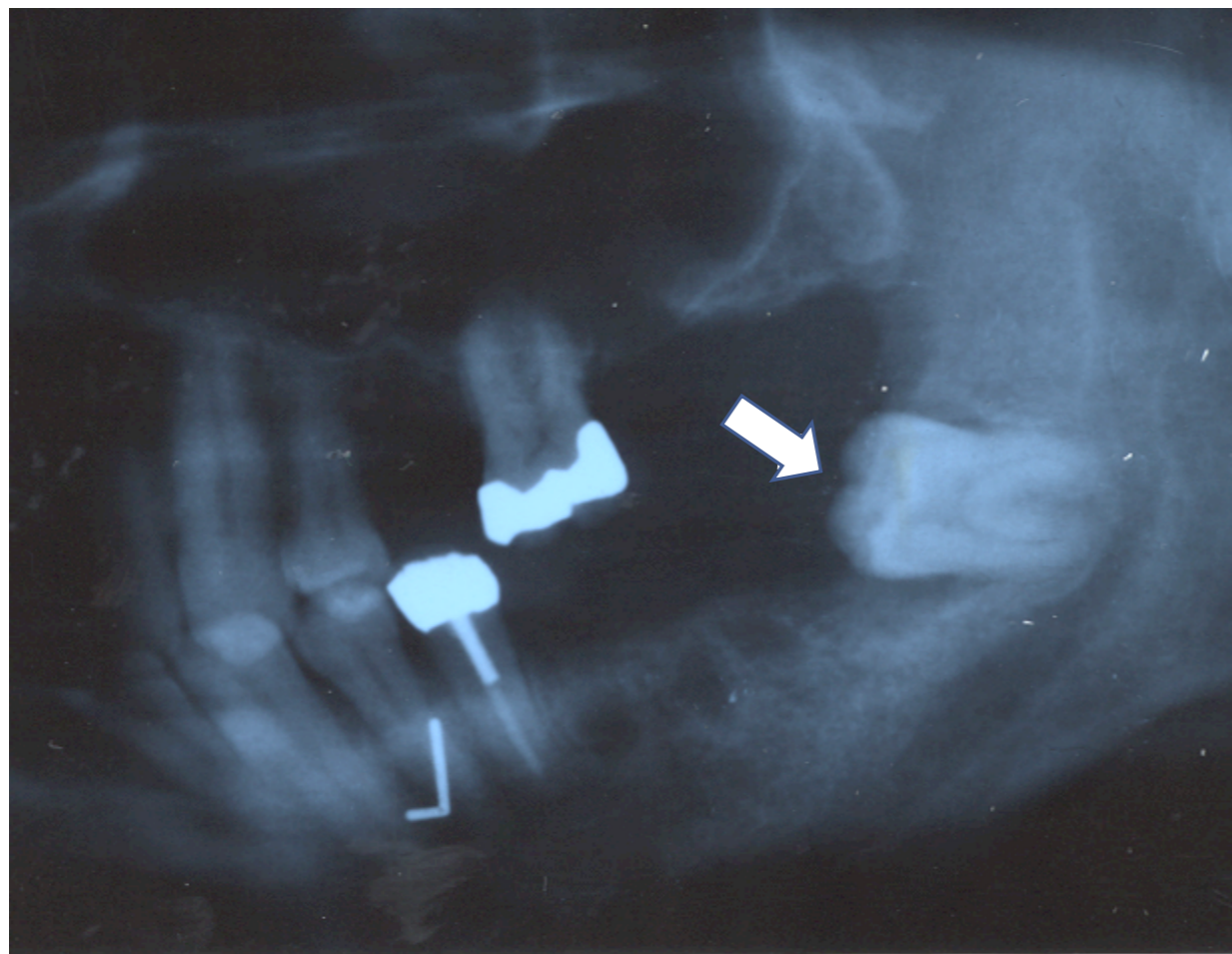
Problems associated with impacted third molars

Third molar interference with fixed prosthetic (crown) treatment plan:



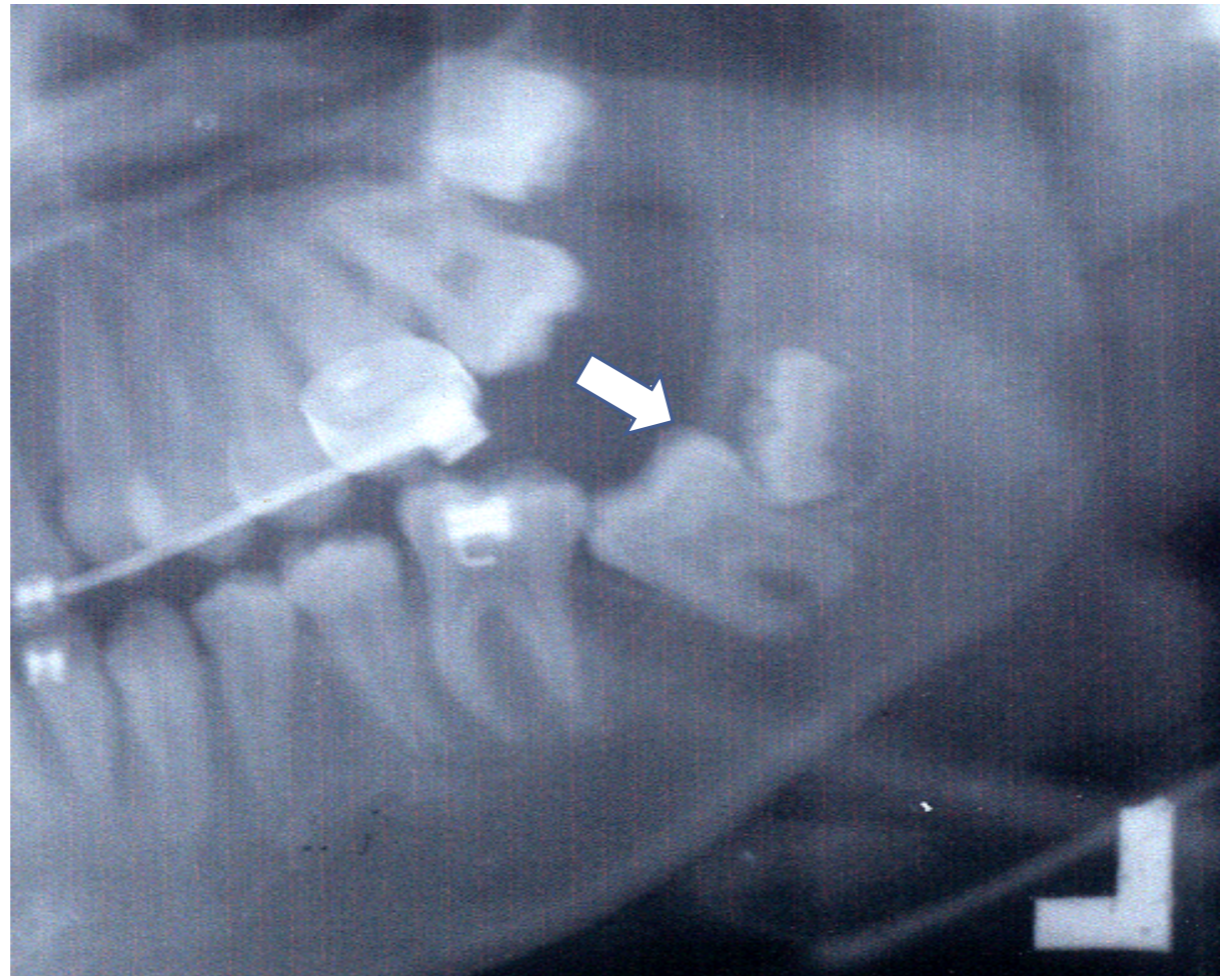
Problems associated with impacted third molars

Retained third molar tooth interference with removable prosthetic treatment plans:



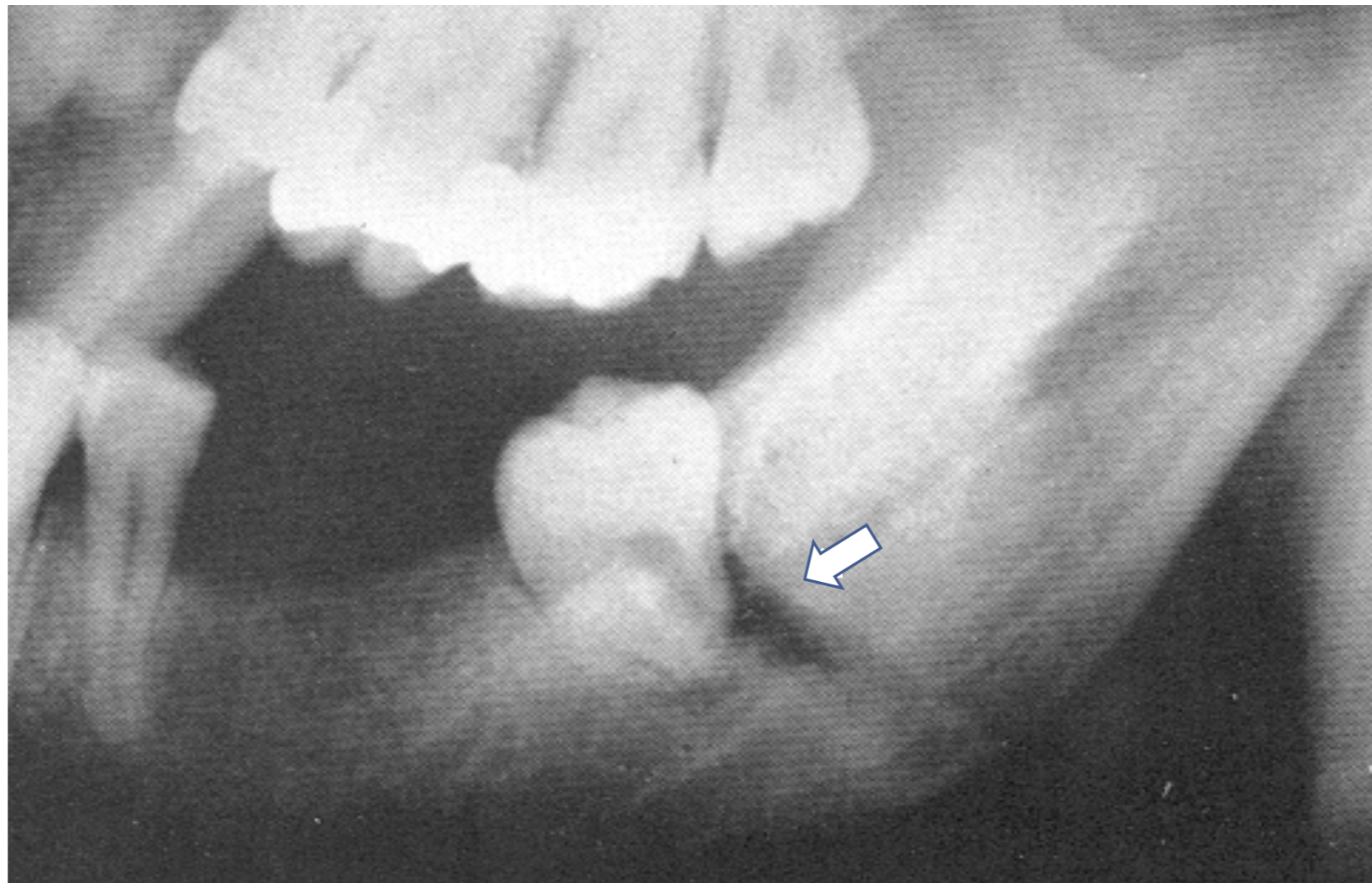
Problems associated with impacted third molars

Impacted third molar interference with eruption of adjacent second molar and orthodontic tooth movement:



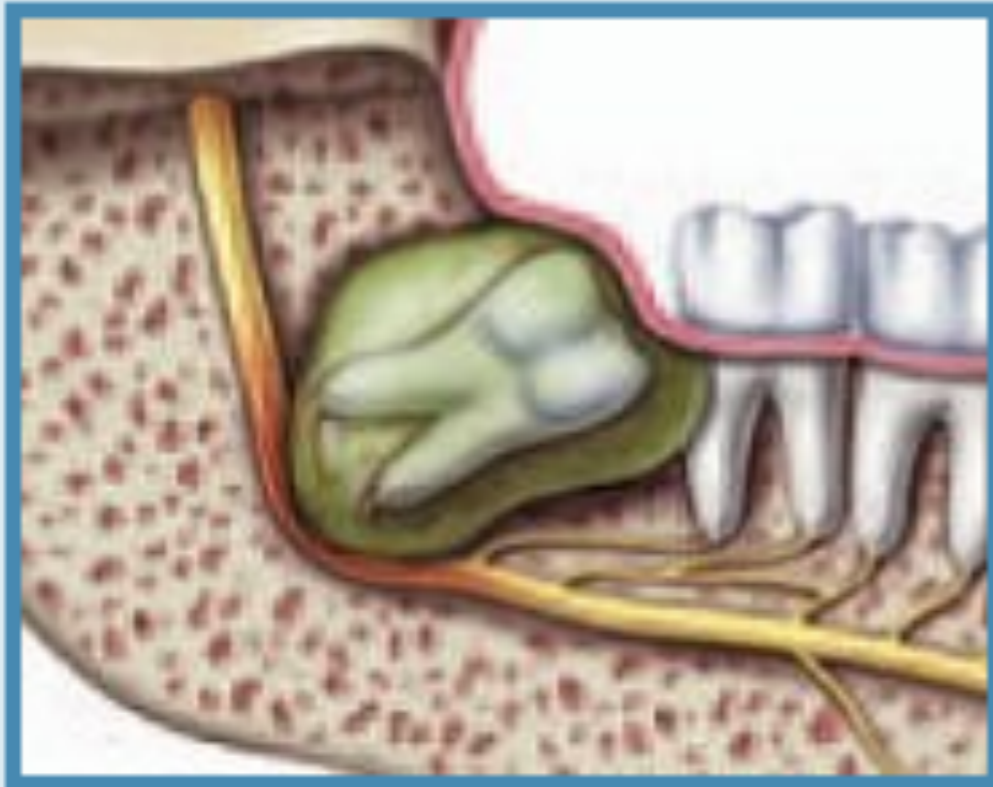
Problems associated with impacted third molars

Impacted third molar in the line of fracture:

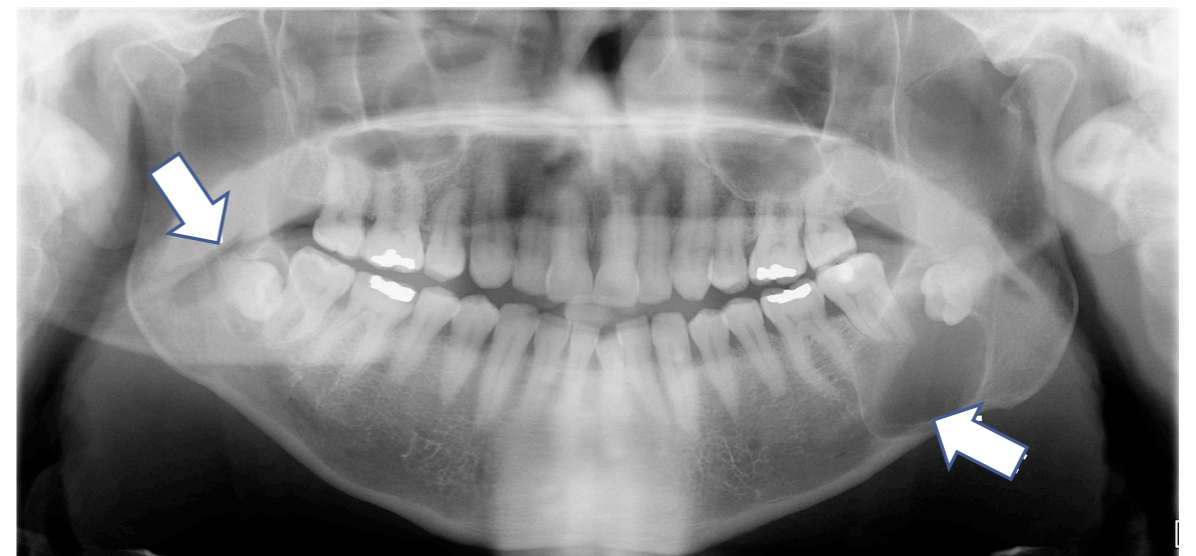

Problems associated with impacted third molars

Cysts and Tumors



(c) Cyst



Bilateral Mandibular Dentigerous Cyst

“Asymptomatic” versus “Disease-Free”

- “Asymptomatic” does not mean “Disease Free”
- Even third molars that have erupted into the mouth in a normal, upright position may not be problem-free.
 - Their location in the back of the mouth makes them extremely difficult to keep clean.
 - Bacteria that cause periodontal disease may exist in and around asymptomatic third molars, leading to damage before symptoms appear.
- Pathology is always present before symptoms appear.
 - Once damage has occurred, it is not always treatable.

Additional risks

- Bacteria may contribute to systemic health problems, including:
 - diabetes,
 - heart disease,
 - kidney disease, and
 - other health problems.
- Studies have found that periodontal disease in expectant mothers may be associated with a greater likelihood of preterm and low birthweight babies.

Research has also shown a relationship between the presence of wisdom teeth and the progression of periodontal disease.

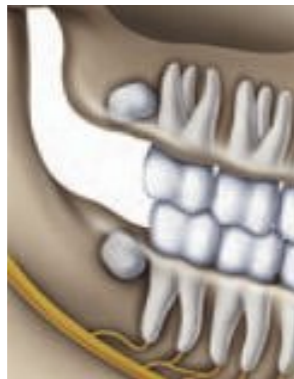- White RP, Offenbacher S, et.al. Chronic oral inflammation and the progression of periodontal pathology in the third molar region. *J Oral Maxillofac Surg.* 64:880, 2006

25% of wisdom teeth patients who perceive themselves as asymptomatic actually already have inflammatory periodontal disease.

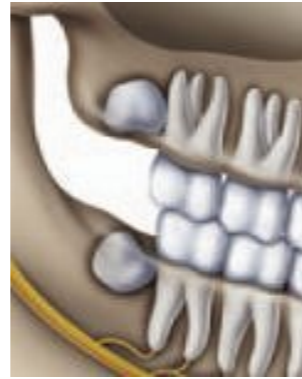- Blakey GH, Marciani RD, Haug RH, et.al: Periodontal pathology associated with asymptomatic third molars; Journal of Oral and Maxillofacial Surgery. 2001;60:1227-1233

The role of age in third molar surgery

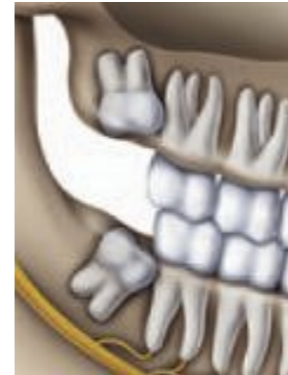- Young adult wisdom teeth have incomplete root systems
- Surgery less complicated
- Healing process quicker.



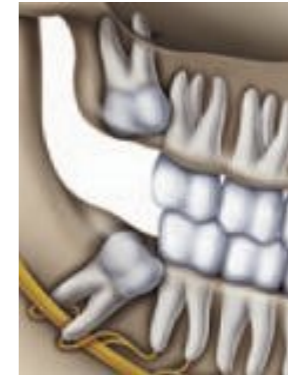12 years



14 years



17 years



24 years

No one can predict when third molar complications will occur, but when they do, the circumstances can be much more painful and the teeth more difficult to treat.

Morbidity associated with surgical management of third molar teeth, as well as the risk of complications, has been shown to increase with age.

- Bui CH, Selodin EB, Dodson TB. Types, frequencies and risk factors for complications after third molar extraction. *J Oral Maxillofac Surg* . 61: 1379, 2003
- Bouloux GF, Steed MB, and Perciaccante VJ. Complications of third molar surgery. *Oral and Maxillofacial Surgery Clinics of North America*. 19:117-128, 2007
- Marciani RD. Third molar removal: An overview of indications, imaging, evaluation, and assessment of risk.. *Oral and Maxillofacial Surgery Clinics of North America*. 19:1-13, 2007

The risk of future disease requiring removal of retained wisdom teeth in asymptomatic patients who retain their wisdom teeth, exceeds 70% after 18 years of follow-up.

- Venta I, Ylipaavalniemi P, Turtola L: Clinical outcome of third molars in adults followed during 18 years. *J Oral Maxillofac Surg.* 62:182, 2004

20 years after UK adopts the “National Institute of Clinical Excellence” (NICE) guidelines, volume of third molar surgeries decrease, with a corresponding increase in mean age for surgical admissions and an increase in “caries” and “pericoronitis” as etiologic factors.

- Renton T, Al-Haboubi M, Pau A, Shepherd J, Gallagher JE: What has been the United Kingdom’s experience with retention of third molars? *J Oral Maxillofac Surg.* 70:48-57, 2012, Suppl 1

Retention of third molars is associated with increased risk of second molar pathology in middle-aged and older adult men.

- Nunn, ME, et al. Retained Asymptomatic Third Molars and Risk for Second Molar Pathology. Nunn et al. *J DENT RES* published online 16 October 2013.

Evidence-based management of third molars

Every dentist and dental specialist should understand the importance of evidence-based management of third molar teeth and office-based anesthesia in the dental office.

What is evidence-based management?

A systematic approach to clinical problem solving which allows the integration of the best available SCIENTIFIC evidence with clinical expertise and patient values.

(Sackett DL, Strauss SE, Richardson WS, et al. Evidence-based medicine: how to practice and teach EBM. London: Churchill-Livingstone, 2000)

Evidence-Based Clinical Decision-Making (EBCD)

- Apply pertinent data to each individual case
- Critically weigh the treatment options
- Choose the best course of action for the patient

Evaluating third molars for surgery

- Every patient and every case is unique.
- Decisions regarding surgery must consider:
 - Careful examination of your mouth;
 - Radiographic examination involving x-rays or a CT-scan; and
 - Consultation between patient, dentist and oral and maxillofacial surgeon with a balanced discussion of the benefits and risks of retention versus benefits and risks of operative management.

Available options

- Depending on the results of the dental examination, the OMS may:
 - Extract the complete tooth;
 - Partially remove the tooth; or
 - Active Surveillance - Observe the tooth over time for changes in condition.

What is “partial removal?”

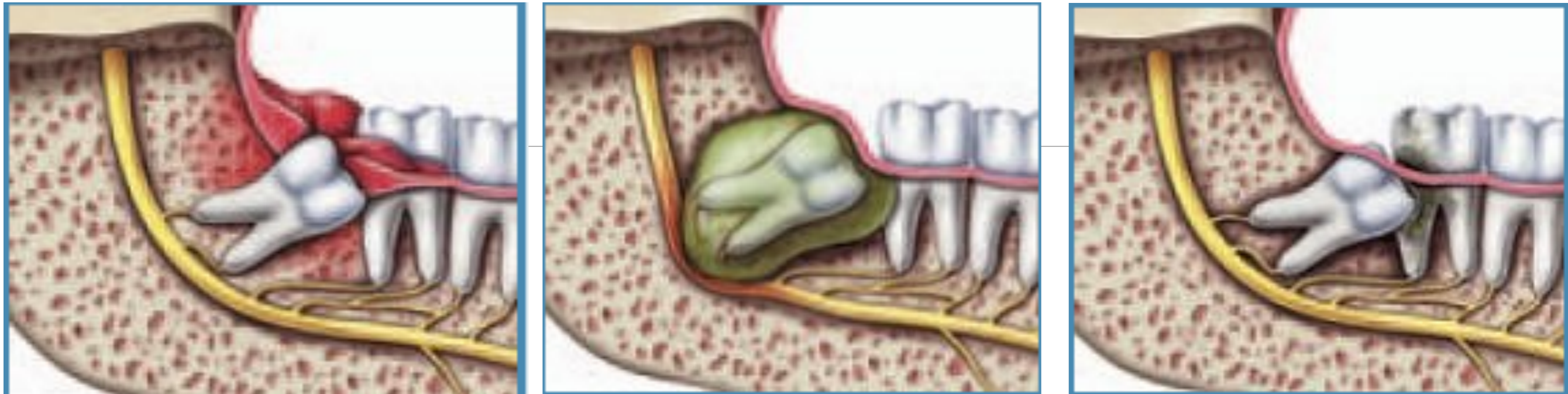Partial removal of third molars, or “Coronectomy,” is a surgical procedure that removes the crown of the tooth and leaves the root and associated nerve complex.

- May be performed when removing the entire tooth might damage the nerve, potentially causing facial numbness.

Pogrel, MA, Lee, JS, Muff, DF: Coronectomy: A Technique to Protect the Inferior Alveolar Nerve. *J Oral Maxillofac Surg.* 1447-1452, 2004

When must third molars be surgically removed?

- In general, dental professionals agree that third molars should be removed whenever there is evidence that predicts:
 - Periodontal disease,
 - Cavities that cannot be restored,
 - Infections,
 - Cysts or tumors, and/or
 - Damage to neighboring teeth.



Removal of wisdom teeth is always appropriate “where there is evidence of pathological changes such as infection, non-restorable carious lesions, cysts, tumors, and damage to adjacent teeth.”

(American Public Health Association (APHA) Statement on Wisdom Teeth, 2008)

Under what circumstances may third molars be retained?

Third molars may not require surgery if they are:

- Completely erupted and functional,
- Painless,
- Free of cavities,
- Disease-free, and
- In a position that can be kept clean and healthy.

AAOMS Third Molar Position Statement

- All patients with impacted teeth should be carefully evaluated by a qualified dentist. Predicated on the best evidence-based data, impacted teeth that demonstrate pathology, or are at high risk of developing pathology, should be surgically managed. In the absence of pathology or significant risk of pathology, active clinical and radiographic surveillance is indicated.
- All third molar teeth should be managed deliberately using an evidence-based approach. Appropriate management of third molar teeth may include removal, partial removal or retention, followed by active clinical and radiographic surveillance to make sure that pathology does not develop.

AAOMS Third Molar Position Statement

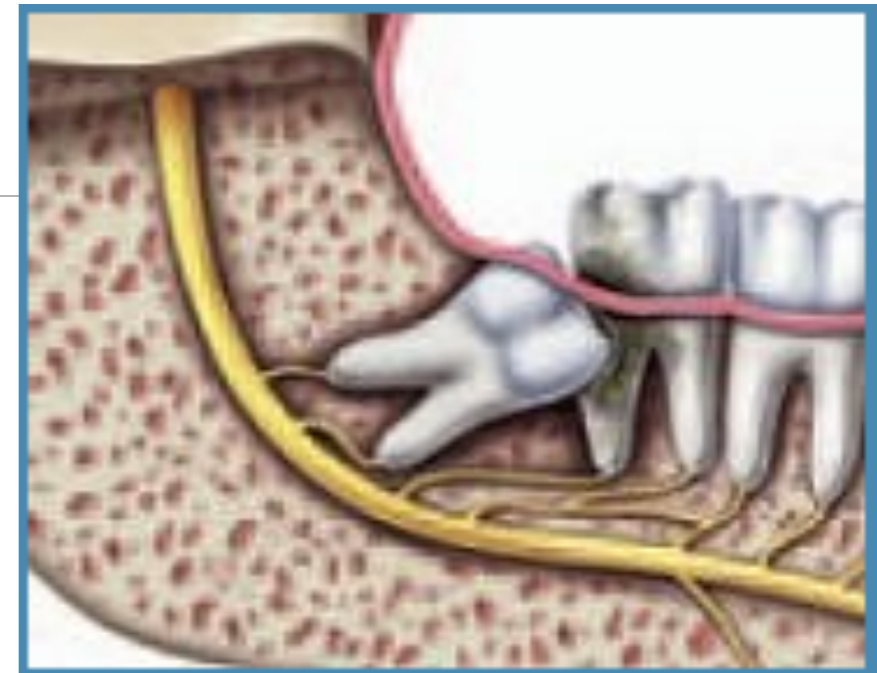
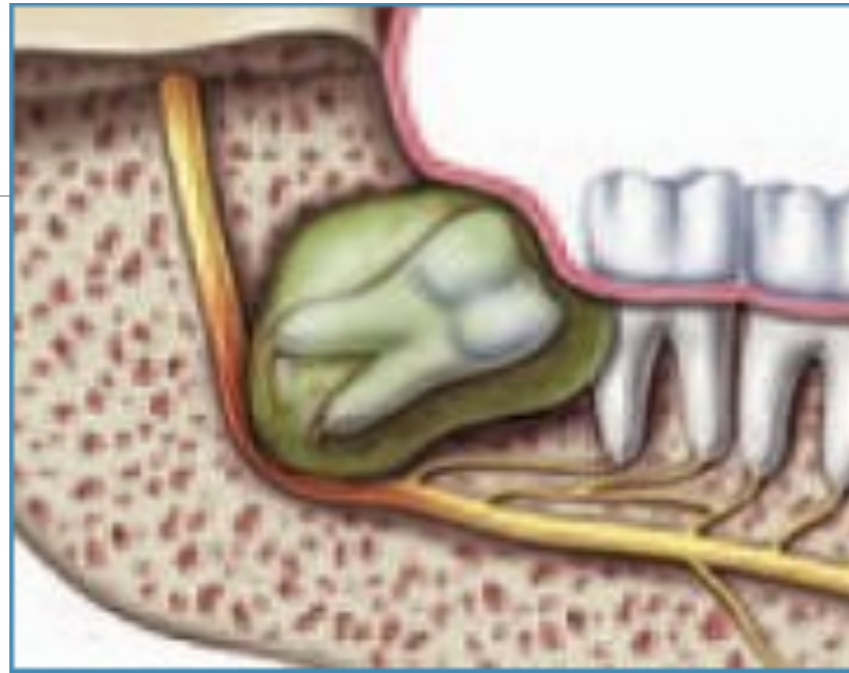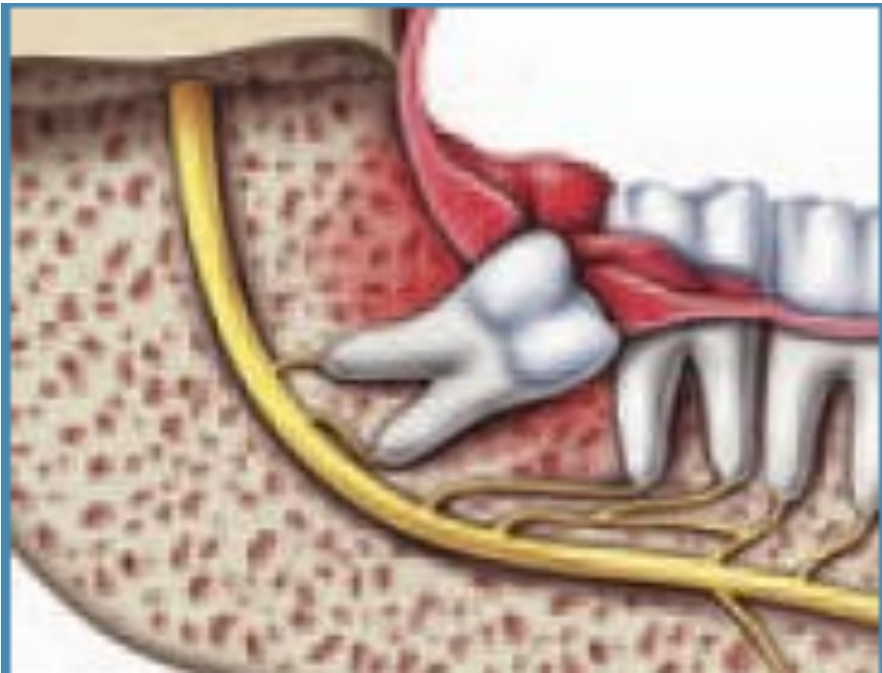- The absence of symptoms does not necessarily mean the absence of disease.
- All third molar teeth should be managed by a qualified dentist. Oral and maxillofacial surgeons surgically manage acute, chronic and potential pathological conditions of third molar teeth.
- Third molar therapy is an evidence-based treatment paradigm. It includes radiographic surveillance to assess tooth position, pathology and possible need for removal. All third molars that are retained require periodic follow-up.

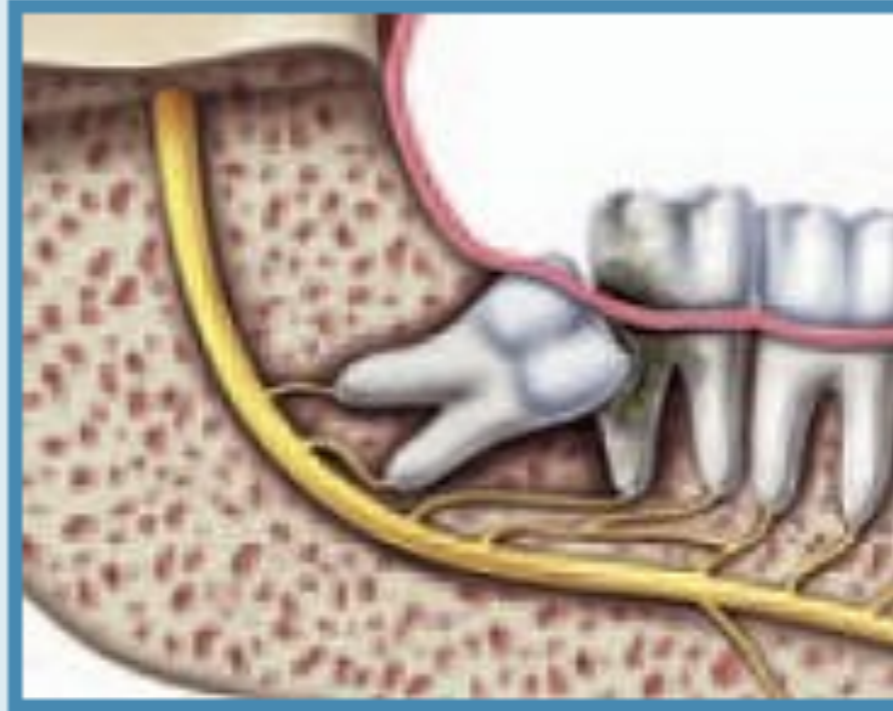
Deliberate management of third molar teeth

The Oral and Maxillofacial Surgeon has the most extensive education and training for appropriate third molar management. This includes:

- Removal
- Partial removal
- Retention with active surveillance

Case Reports

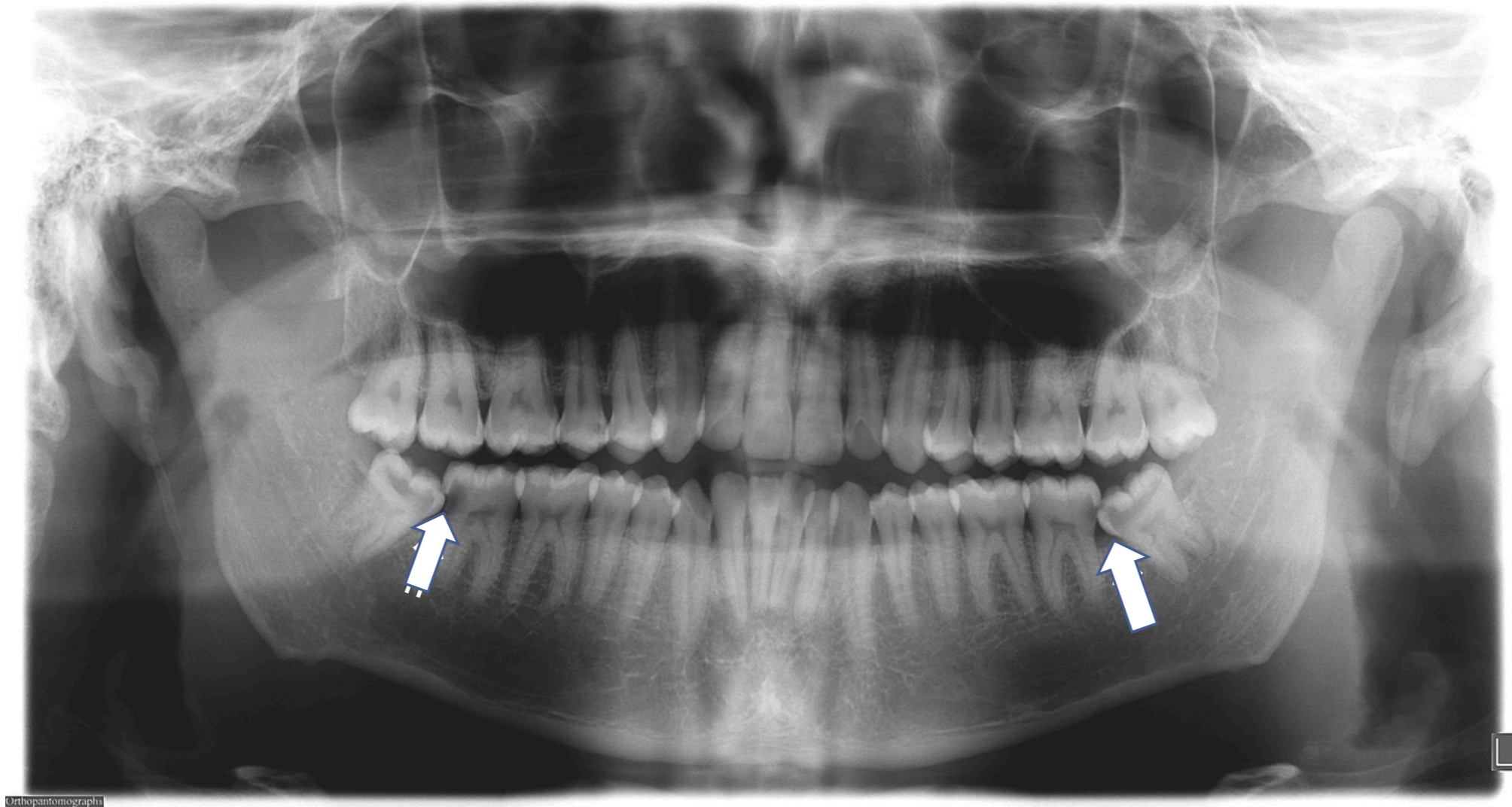




(b) Damage to neighboring teeth

A 32 year-old physician presented with bilateral jaw pain that started one week previously. Prior to this episode, he was completely asymptomatic. Examination revealed malposed and impacted third molar teeth with gross caries involving teeth #s 17, 18, 31 and 32.

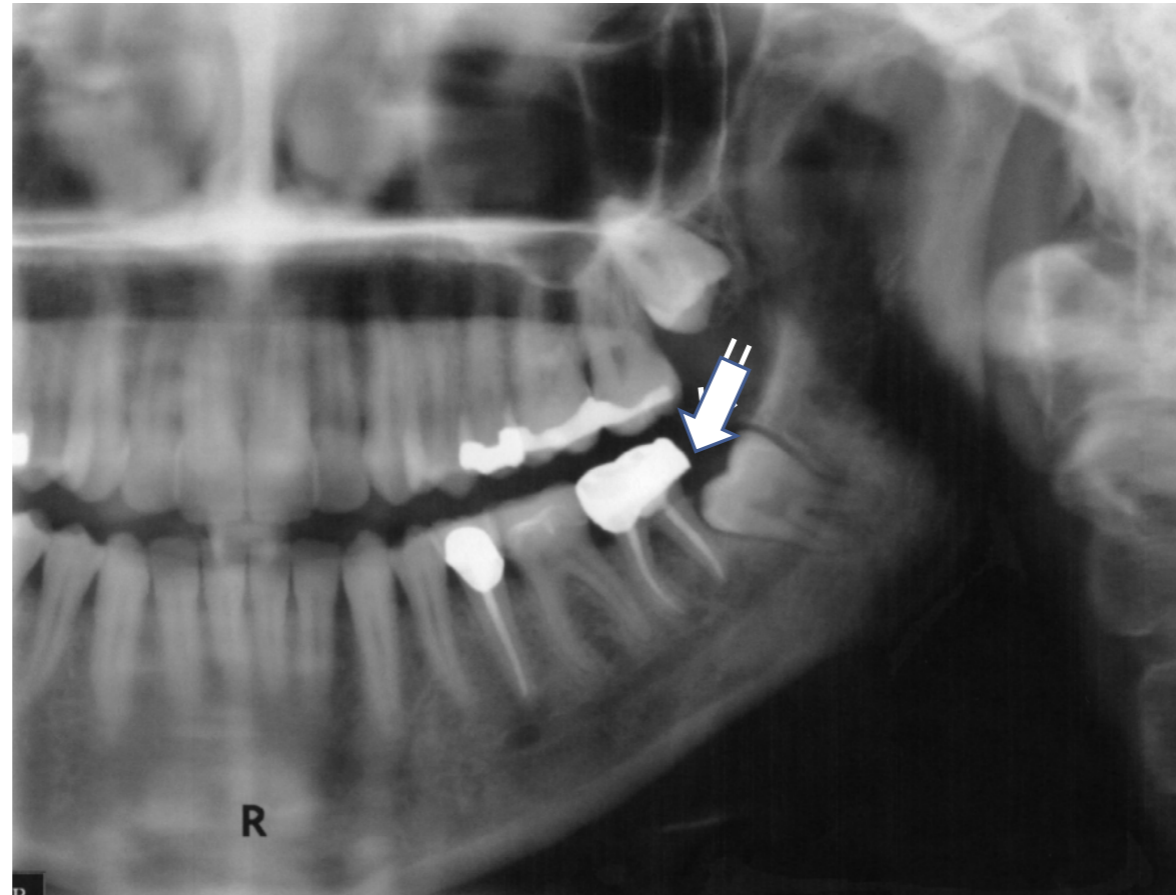
Carious mandibular second and third molar teeth



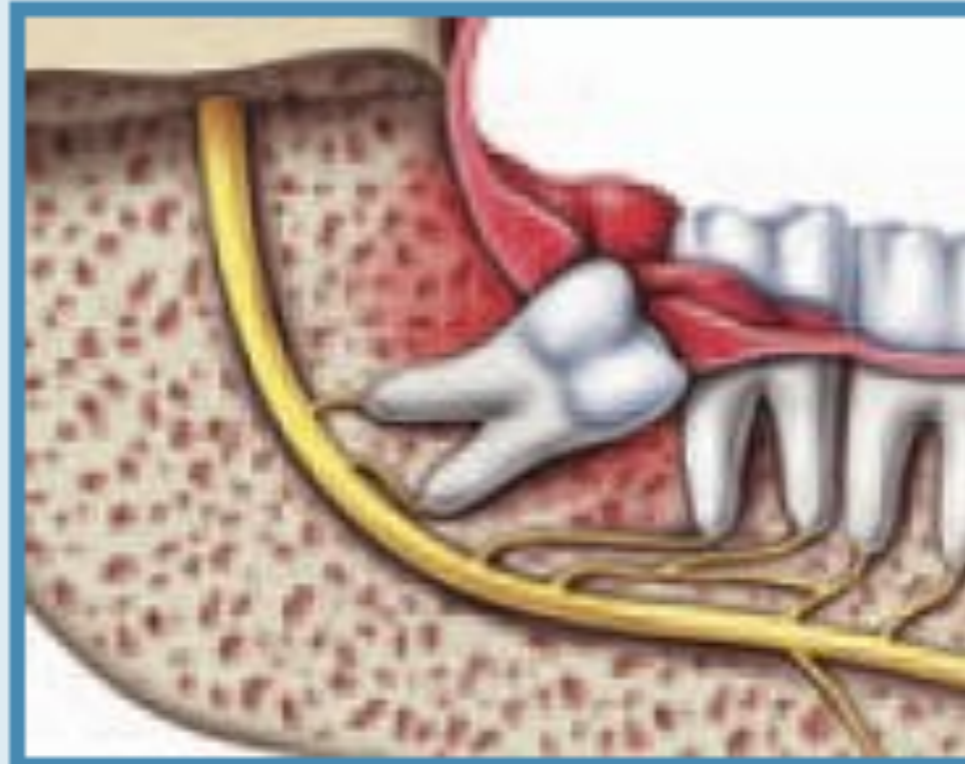

(b) Damage to neighboring teeth

A 39 year-old female patient is evaluated prior to crown replacement at the lower left second molar tooth #18.



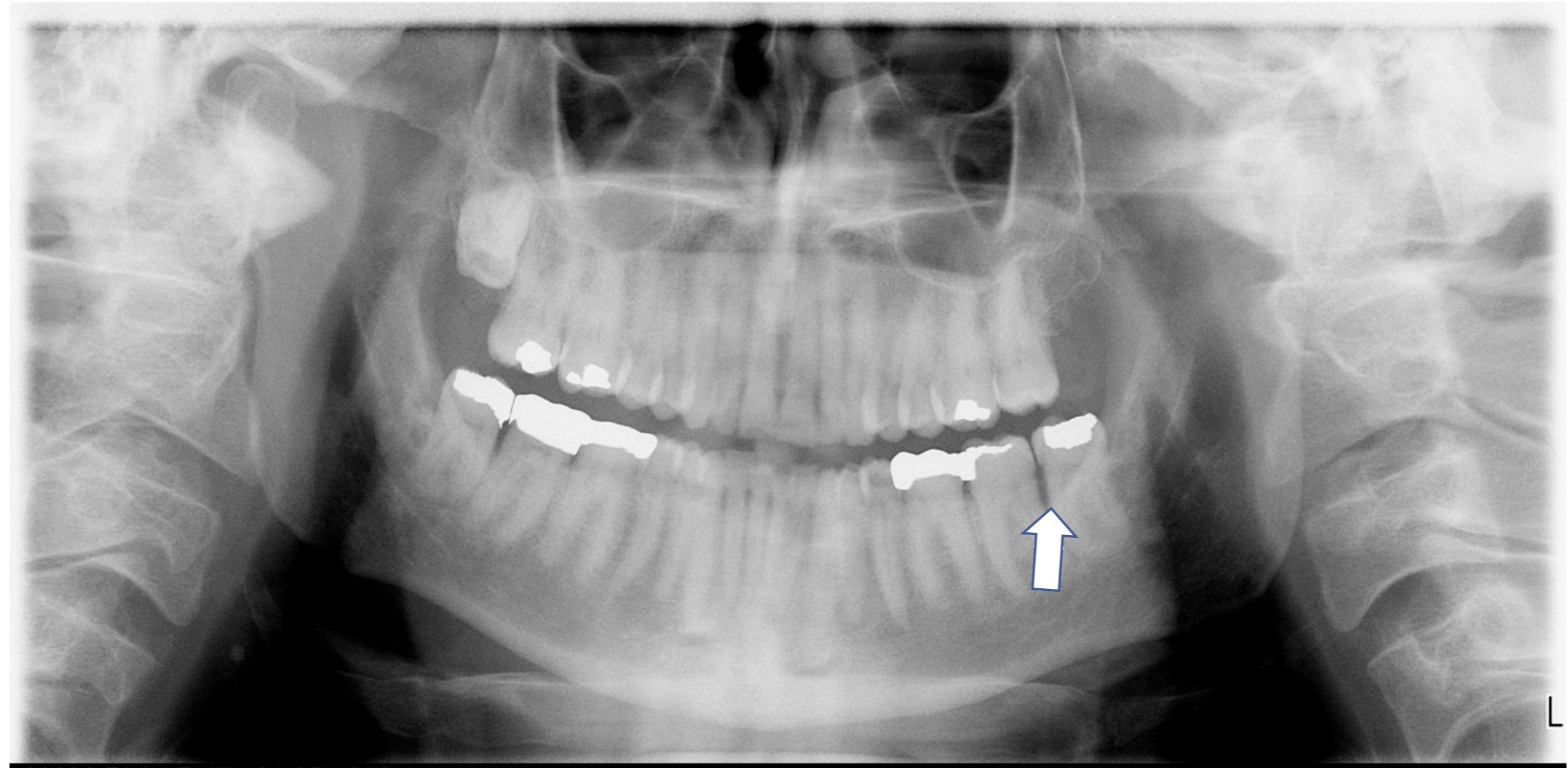
This 39 year old female patient is scheduled for replacement of crown #18. The impacted third molar teeth should first be appropriately managed.

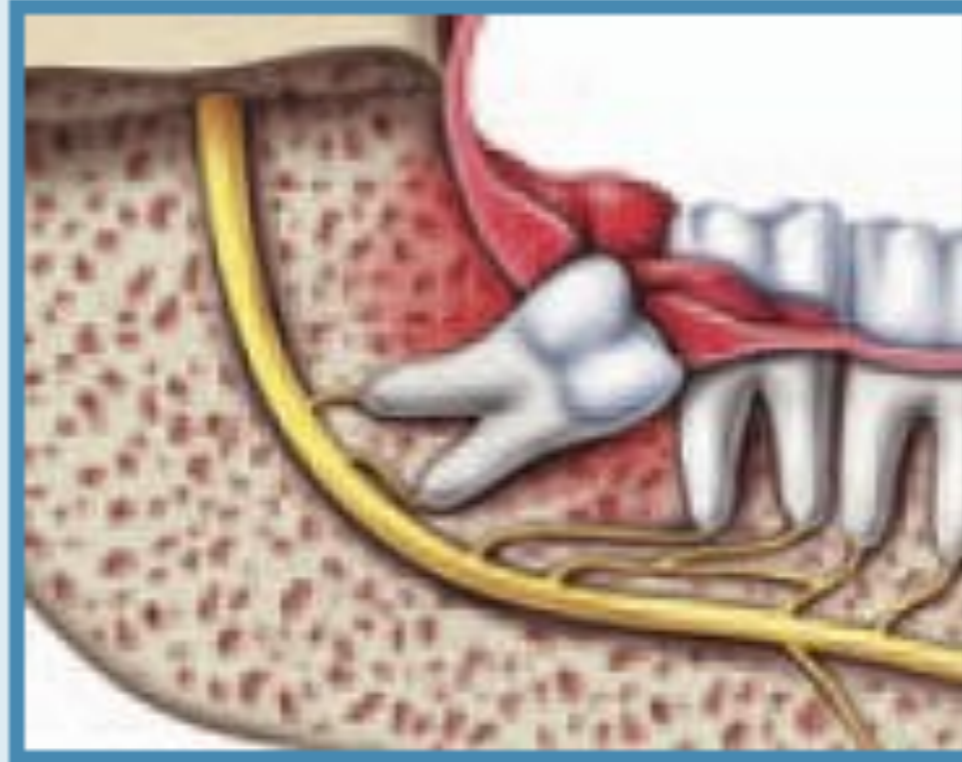


(a) Infection

An otherwise healthy 63 year-old male patient (also a physician) presented to the office with complaints of pain and swelling associated with the area of the mandibular left third molar tooth #17. Clinical examination revealed recurrent caries, pericoronitis and a mesial periodontal probing depth of 8mm.

Periodontal bone loss and pericoronitis

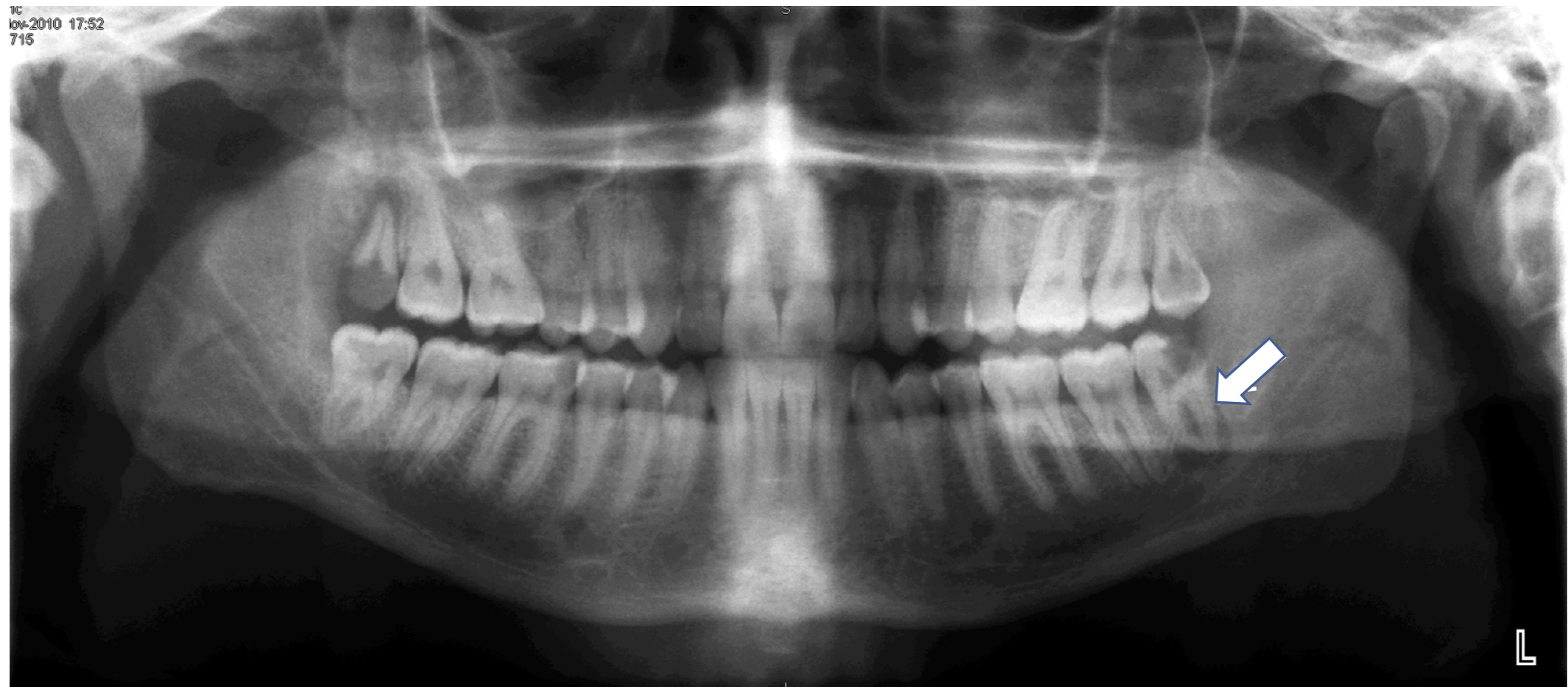




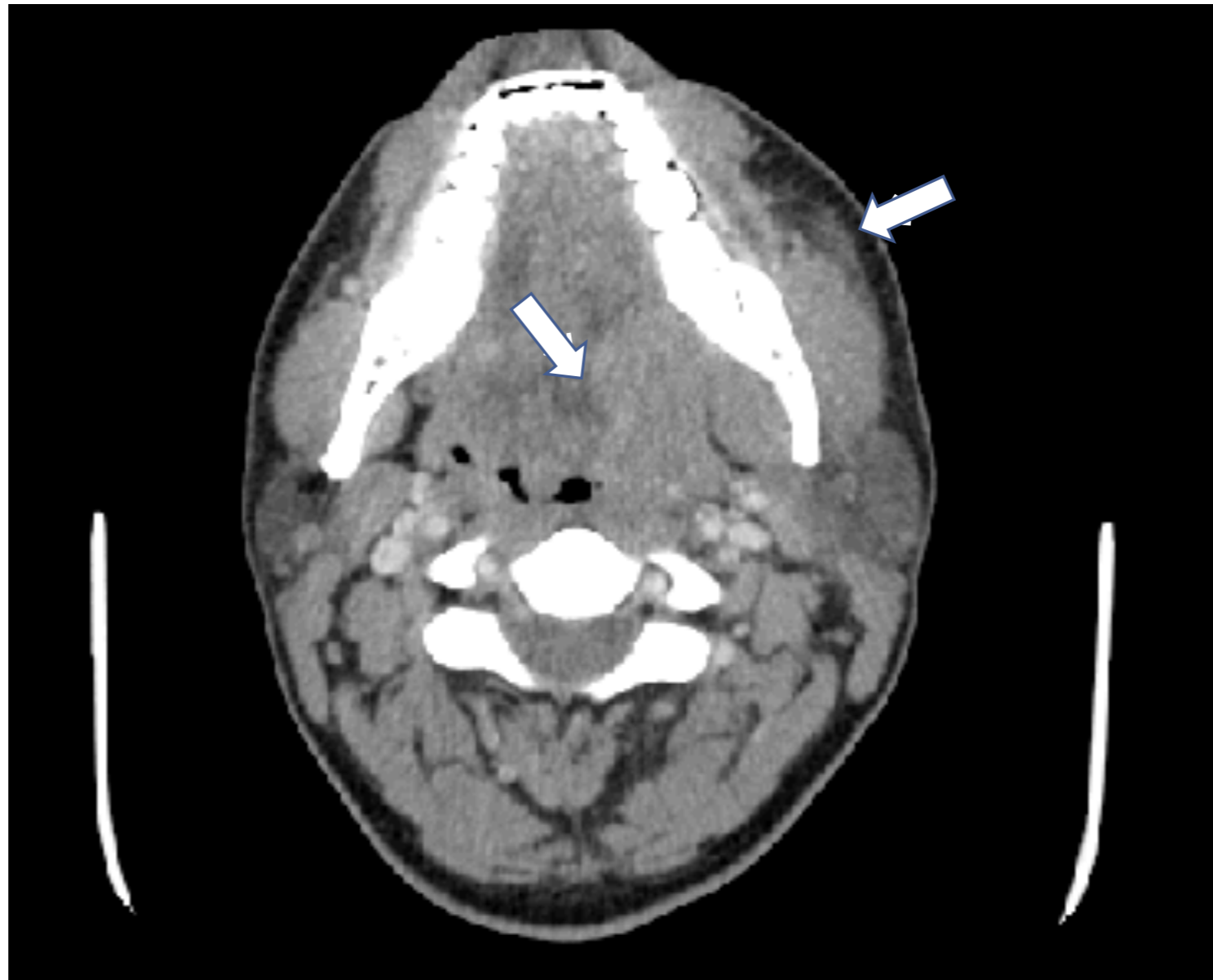
(a) Infection

An otherwise healthy 25 year-old male patient presented to the hospital emergency department with complaints of severe pain and swelling of the left face and neck, trismus, and difficulty swallowing, speaking and breathing. Clinical examination and a CT scan showed an abscessed lower left wisdom tooth with infection of the left submandibular, masseteric, medial pterygoid and sublingual spaces. A shift of the airway to the right was beginning on the CT scan. Laboratory values were consistent with acute infection.

Abscessed mandibular left third molar tooth



Coronal CT scan of odontogenic infection



Clinical examination revealed severe soft tissue cellulitis

CT SCAN OF THE SOFT TISSUES OF THE NECK WITH CONTRAST-

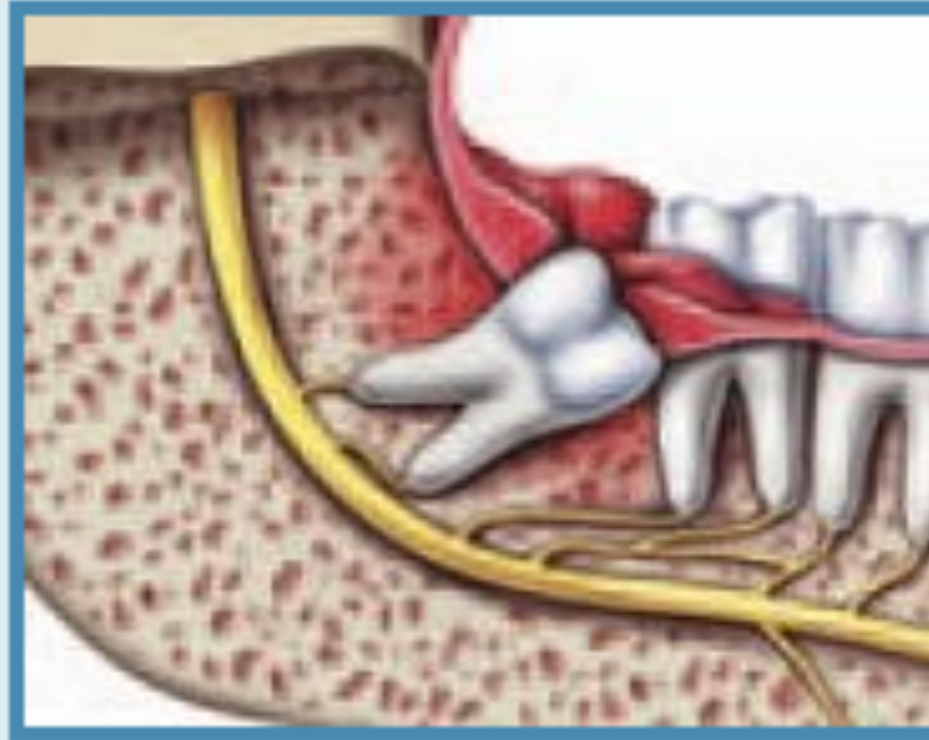
HISTORY- Infection, pain, and swelling.

IMPRESSION-

1. Abscessed tooth in the left side of the mandible.
2. There is soft tissue swelling in the submandibular region on the left and upper neck. A reactive lymph node and slight enlargement of the submandibular gland on the left. No evidence of abscess formation.

Although the radiology report for the CT scan showed “soft tissue swelling [cellulitis]” with, “No evidence of abscess formation,” copious pus was produced upon surgical incision and drainage of the infection.

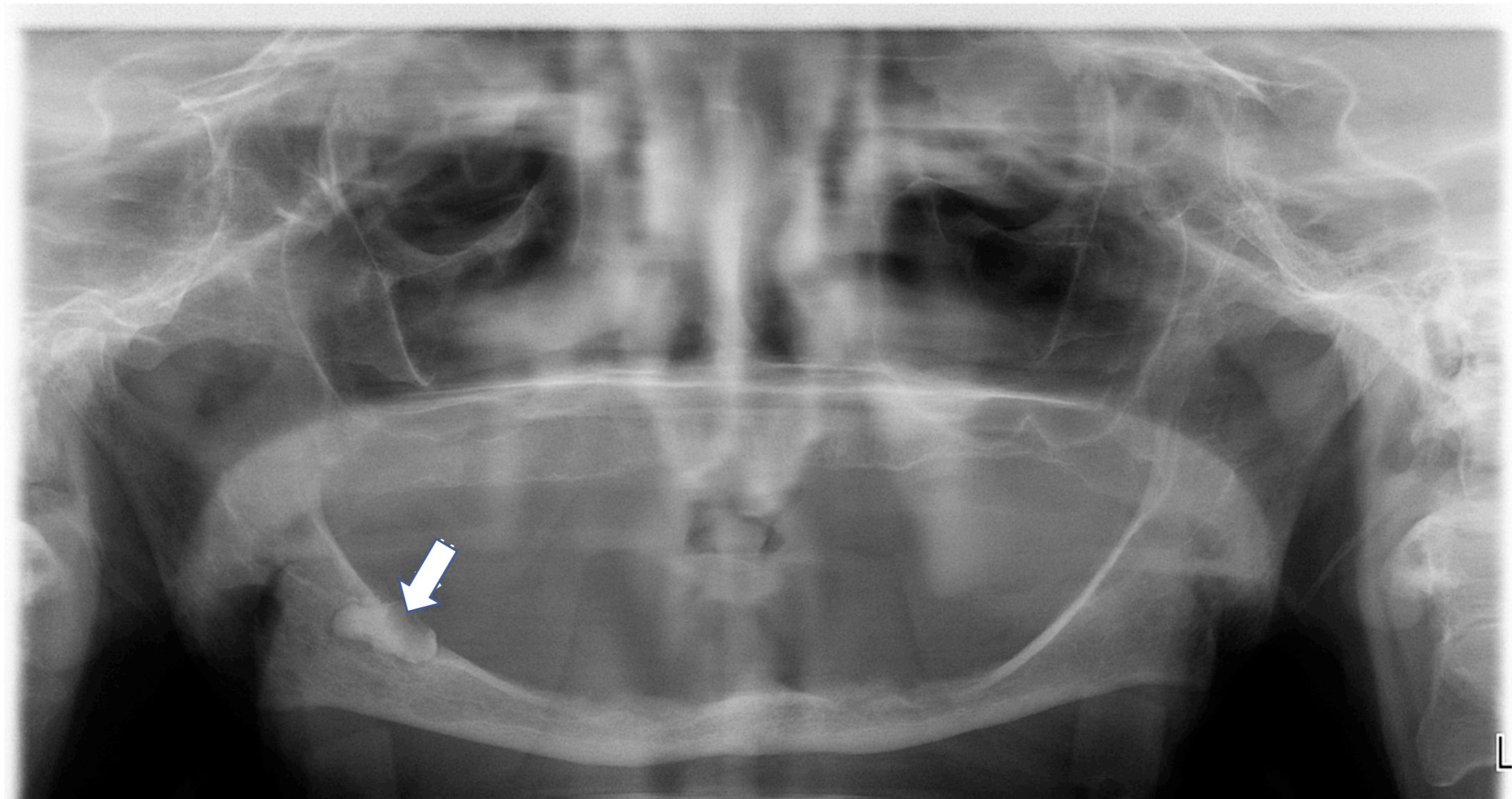
	Result Name	Results	Units	Reference Range
<input checked="" type="checkbox"/>	WBC	19.5 H	10x3/uL	4.8-10.8
<input checked="" type="checkbox"/>	RBC	4.20 L	10x6/uL	4.60-6.20
<input checked="" type="checkbox"/>	HEMOGLOBIN	12.7 L	gm/dl	14.0-18.0
<input checked="" type="checkbox"/>	HEMATOCRIT	36.9 L	%	42.0-52.0
<input checked="" type="checkbox"/>	MCV	88.0	mm3	80-94
<input checked="" type="checkbox"/>	MCH	30	pg	27-31
<input checked="" type="checkbox"/>	MCHC	34	gm/dl	32-36
<input checked="" type="checkbox"/>	PLATELET COUNT	265	10x3/uL	140-340
<input checked="" type="checkbox"/>	MPV	8.1 L	fL	8.8-12.0
<input checked="" type="checkbox"/>	RDW	13.0	%	11.5-14.5
<input checked="" type="checkbox"/>	LYMPHOCTYE	4 L	%	5-55
<input checked="" type="checkbox"/>	MONOCYTE	4	%	0-15
<input checked="" type="checkbox"/>	NEUTROPHIL	92 H	%	40-80
<input checked="" type="checkbox"/>	EOSINOPHIL	0 L	%	1-4
<input checked="" type="checkbox"/>	BASOPHIL	0	%	0-1
<input checked="" type="checkbox"/>	ABSOLUTE LYMPHS	0.9 L	10x3/uL	1.0-5.0
<input checked="" type="checkbox"/>	ABSOLUTE MONOS	0.7	10x3/uL	0.0-1.0
<input checked="" type="checkbox"/>	ABSOLUTE NEUTS	17.9 H	10x3/uL	1.8-7.8
<input checked="" type="checkbox"/>	ABSOLUTE EOS	0.0	10x3/uL	0.0-0.7
<input checked="" type="checkbox"/>	ABSOLUTE BASOS	0.0	10x3/uL	0.0-0.2



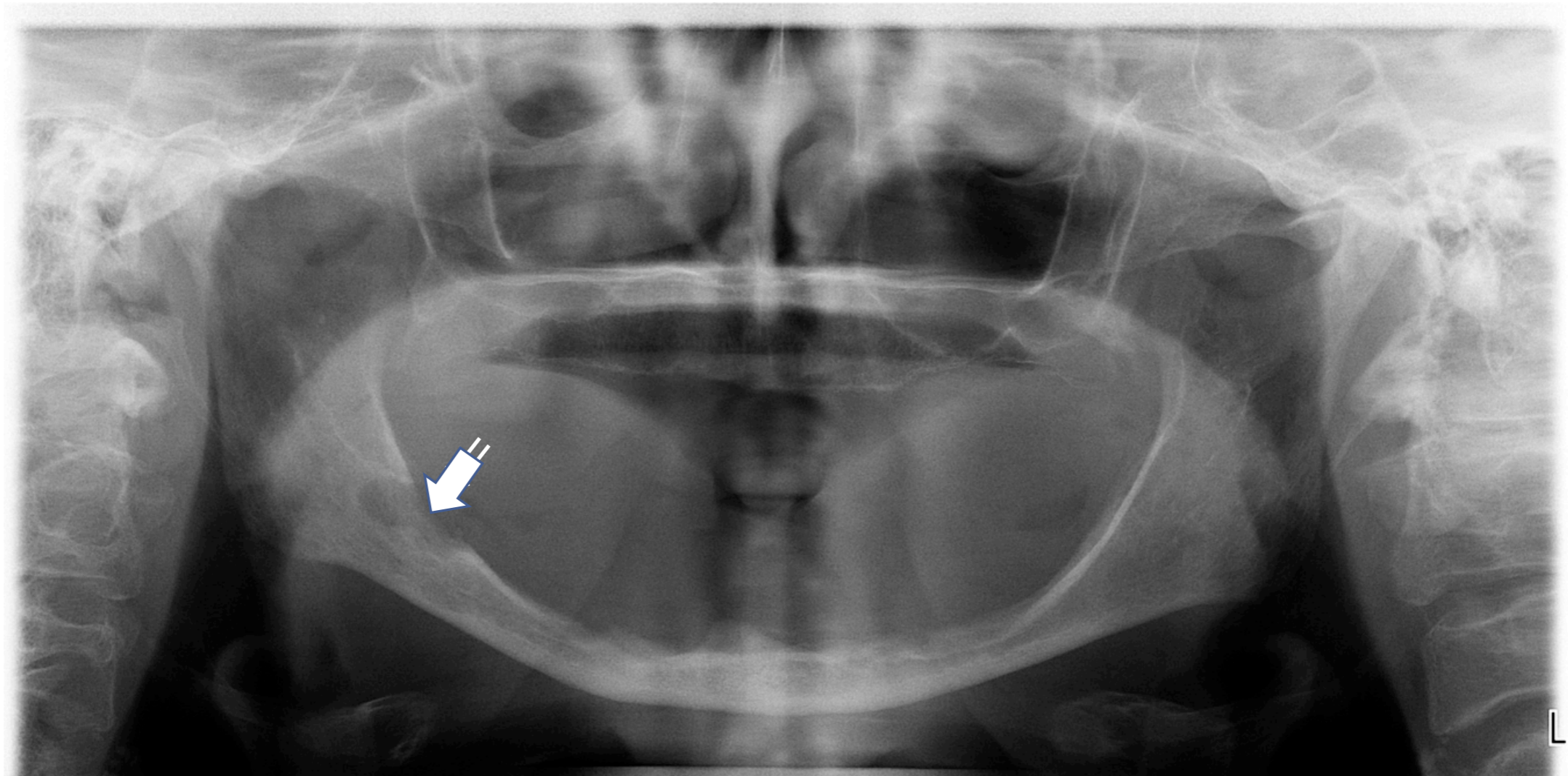
(a) Infection

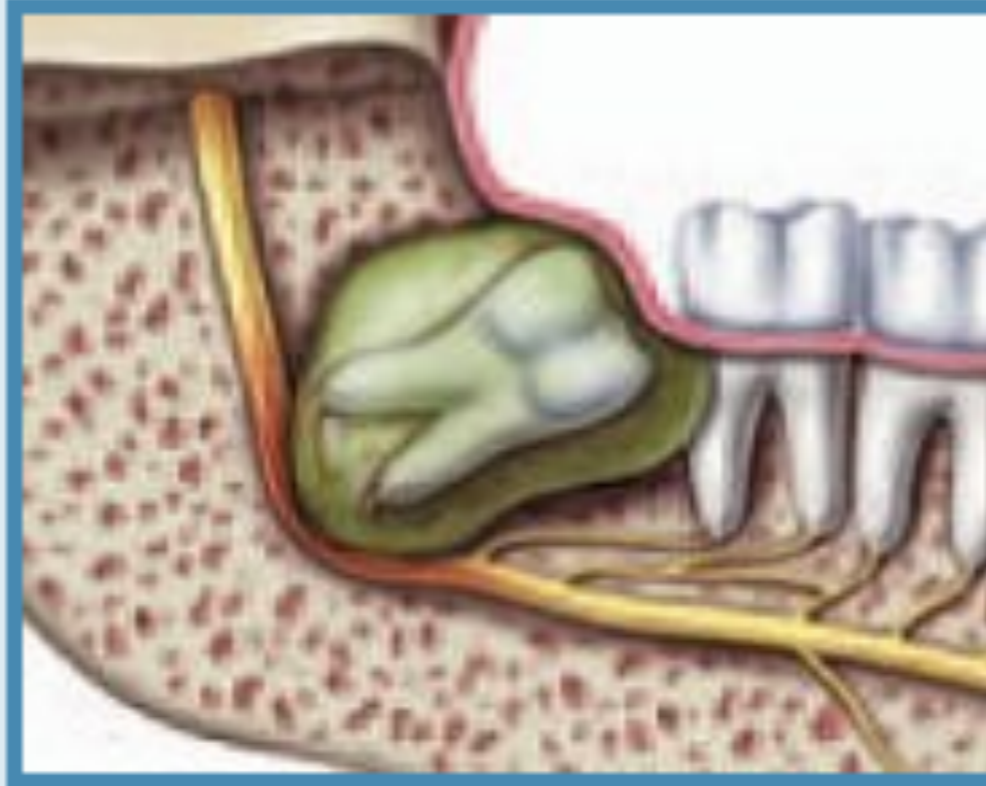An 80 year-old female seen at a local hospital with a right facial infection underwent emergent incision and drainage by an ENT surgeon who placed her on antibiotics and referred her to the OMS. When first seen by the OMS, she was infected and in severe pain. Clinical and radiographic evaluation revealed a severely atrophic mandible with a grossly carious impacted mandibular right third molar tooth with an associated radiolucency (odontogenic cyst).

Atrophic mandible with carious impacted right third molar tooth #32 and cyst



Postoperative radiograph following removal of tooth #32 and associated cyst

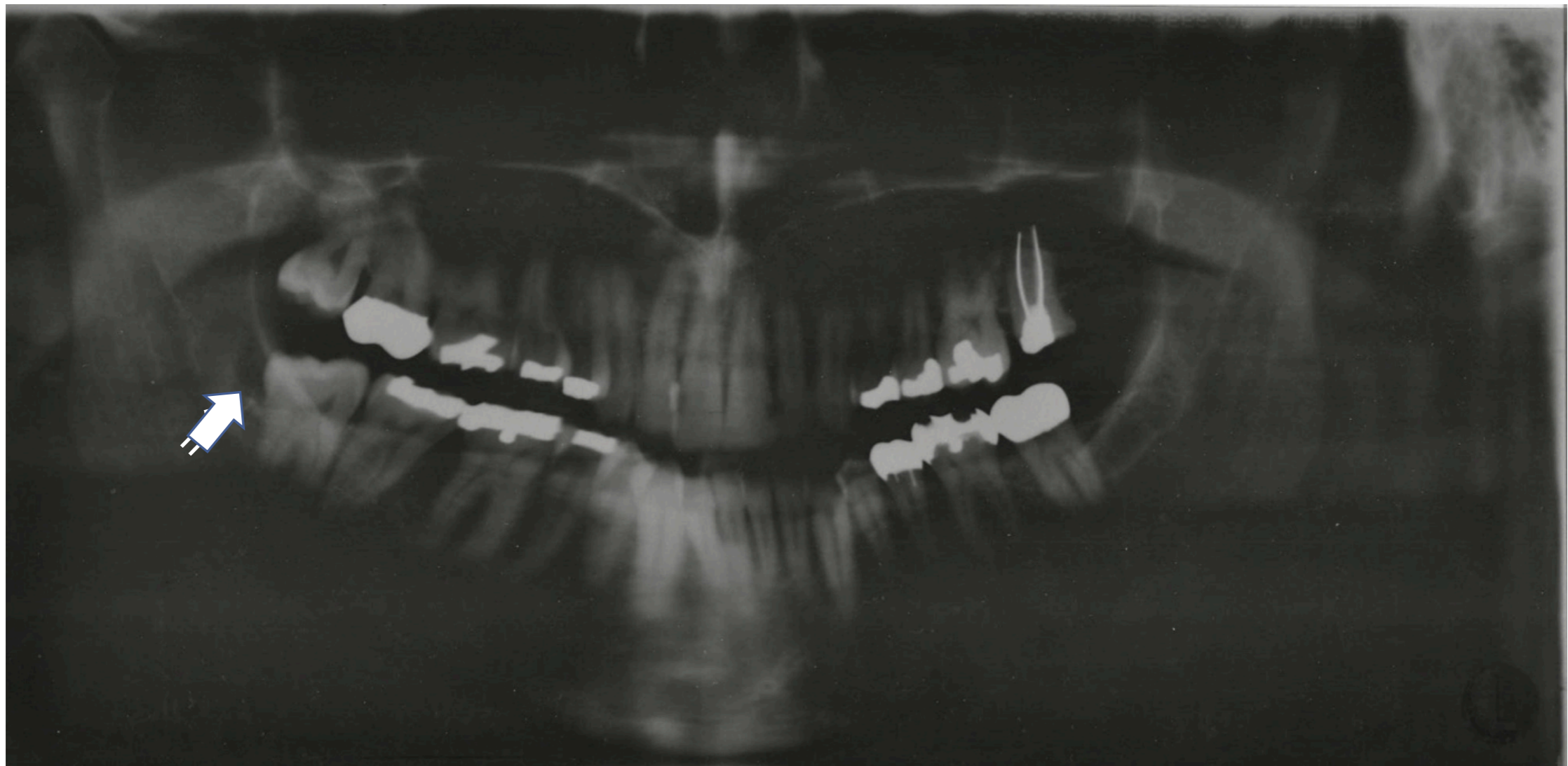




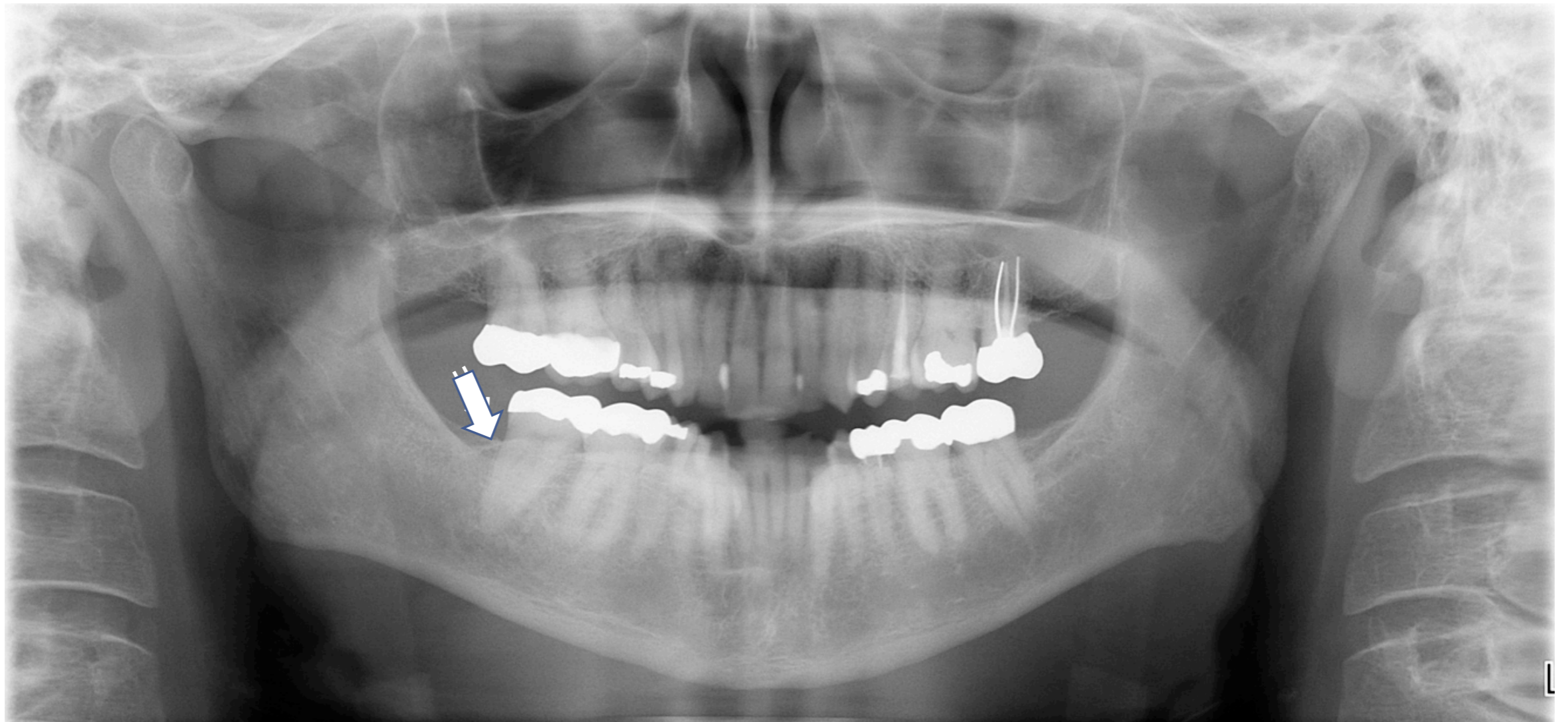
(c) Cyst

A 42 year-old male experienced pain and swelling associated with his right mandibular wisdom tooth that was consistent with pericoronitis. His symptomatic left maxillary and mandibular wisdom teeth were uneventfully removed when he was 18 years-old. Clinical and radiographic evaluation revealed probing depths $>7\text{mm}$ and a pericoronal radiolucency (dentigerous cyst) at tooth #32.

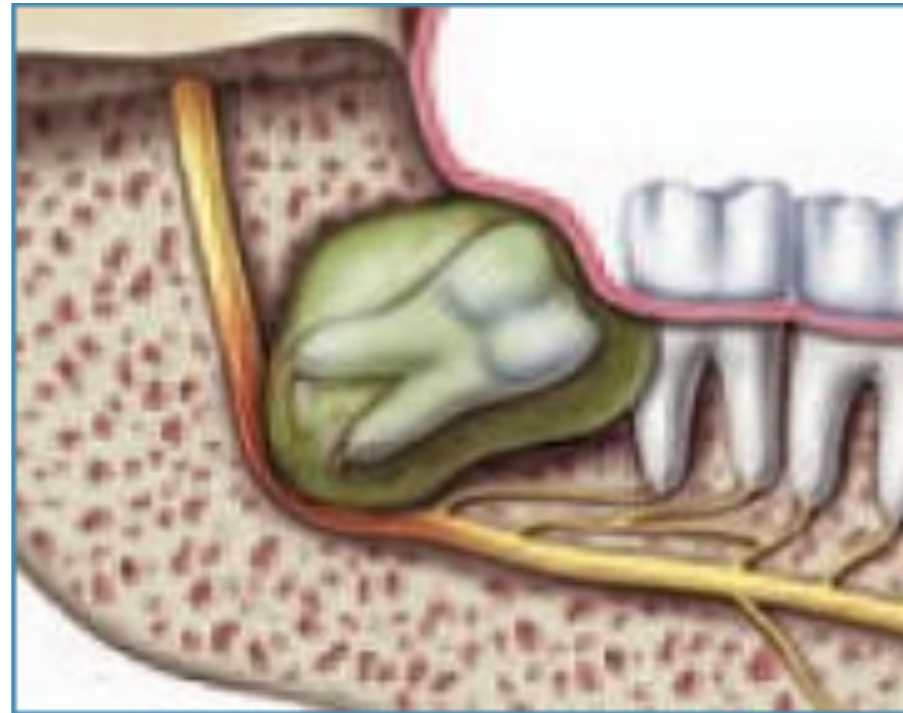Mandibular right third molar tooth #32 with pericoronitis and dentigerous cyst



Perioperative boney defect right posterior mandible

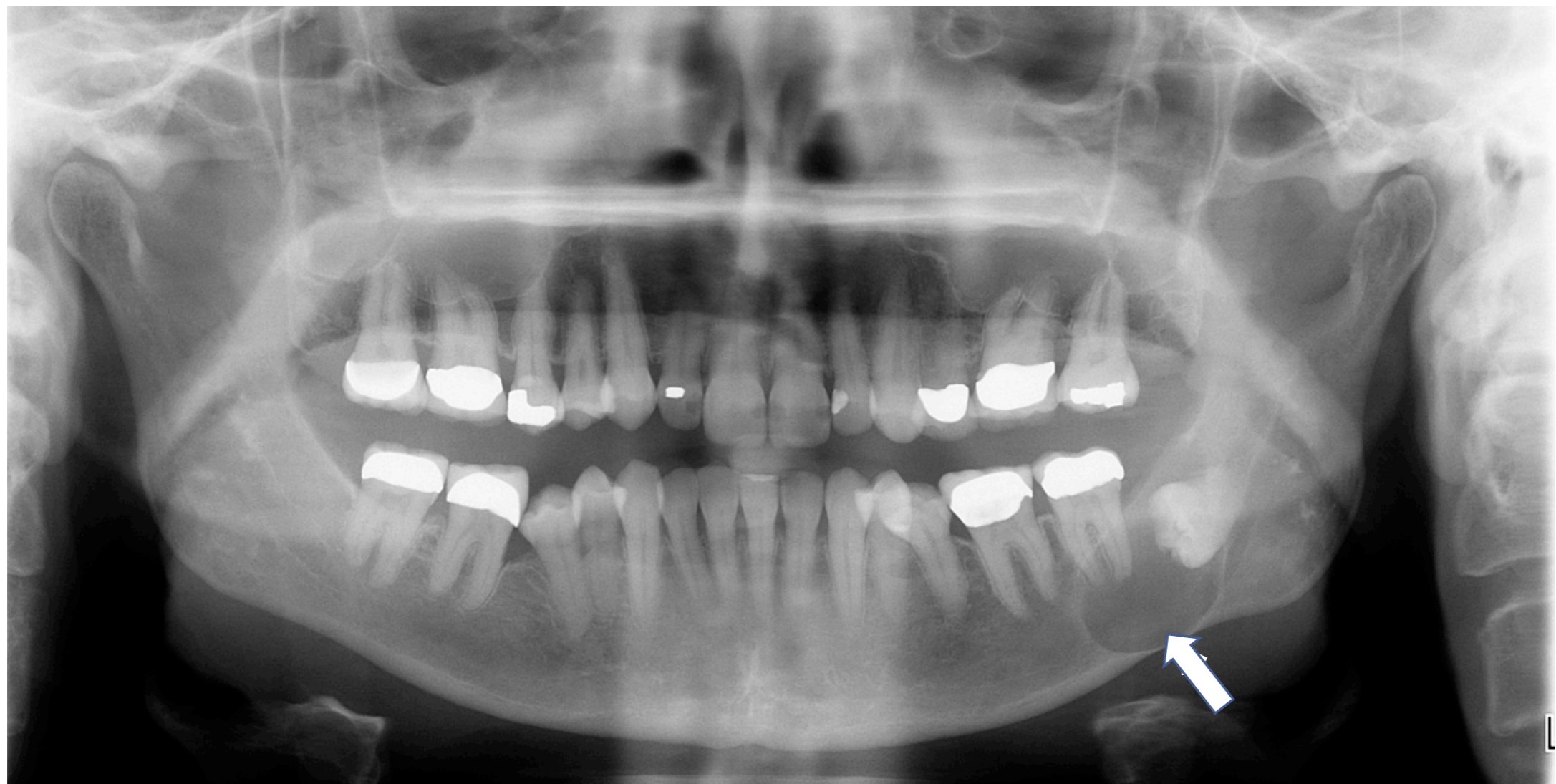

Odontogenic cyst

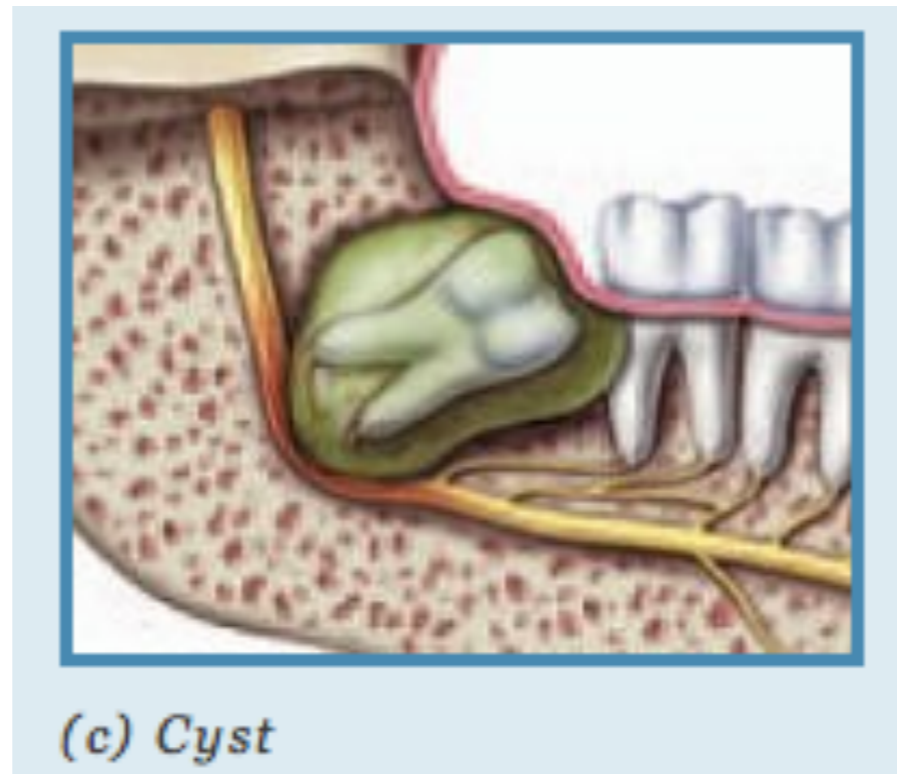


A 66 year-old female experienced mild intermittent pain associated with her previously asymptomatic left mandibular “wisdom” tooth. Clinical and radiographic evaluation revealed a large pericoronal radiolucency (Dentigerous Cyst) at impacted tooth #17.

Left mandibular dentigerous cyst

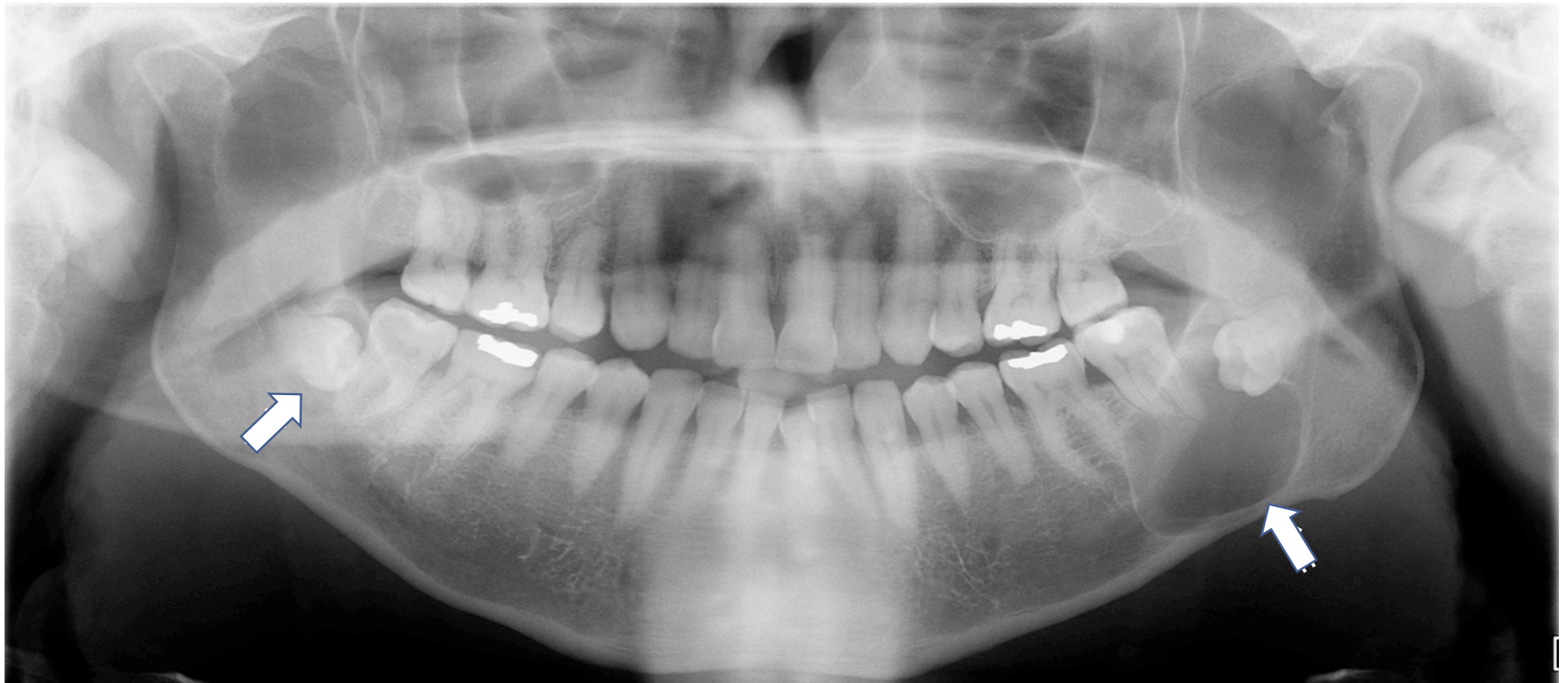

Bilateral odontogenic cysts

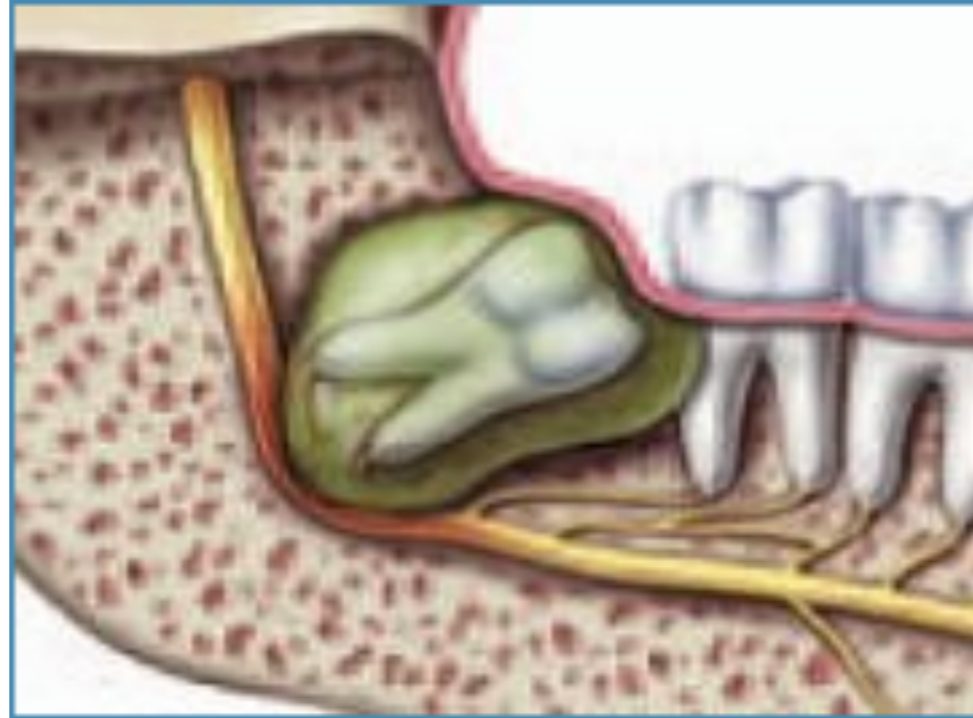

A 47 year-old male experienced pain and swelling associated with his left mandibular wisdom tooth. Clinical and radiographic evaluation revealed a large pericoronal radiolucency (dentigerous cyst) at tooth #17, a smaller pericoronal radiolucency (dentigerous cyst) at tooth #32, and carious mandibular second molar teeth.

Bilateral mandibular dentigerous cysts

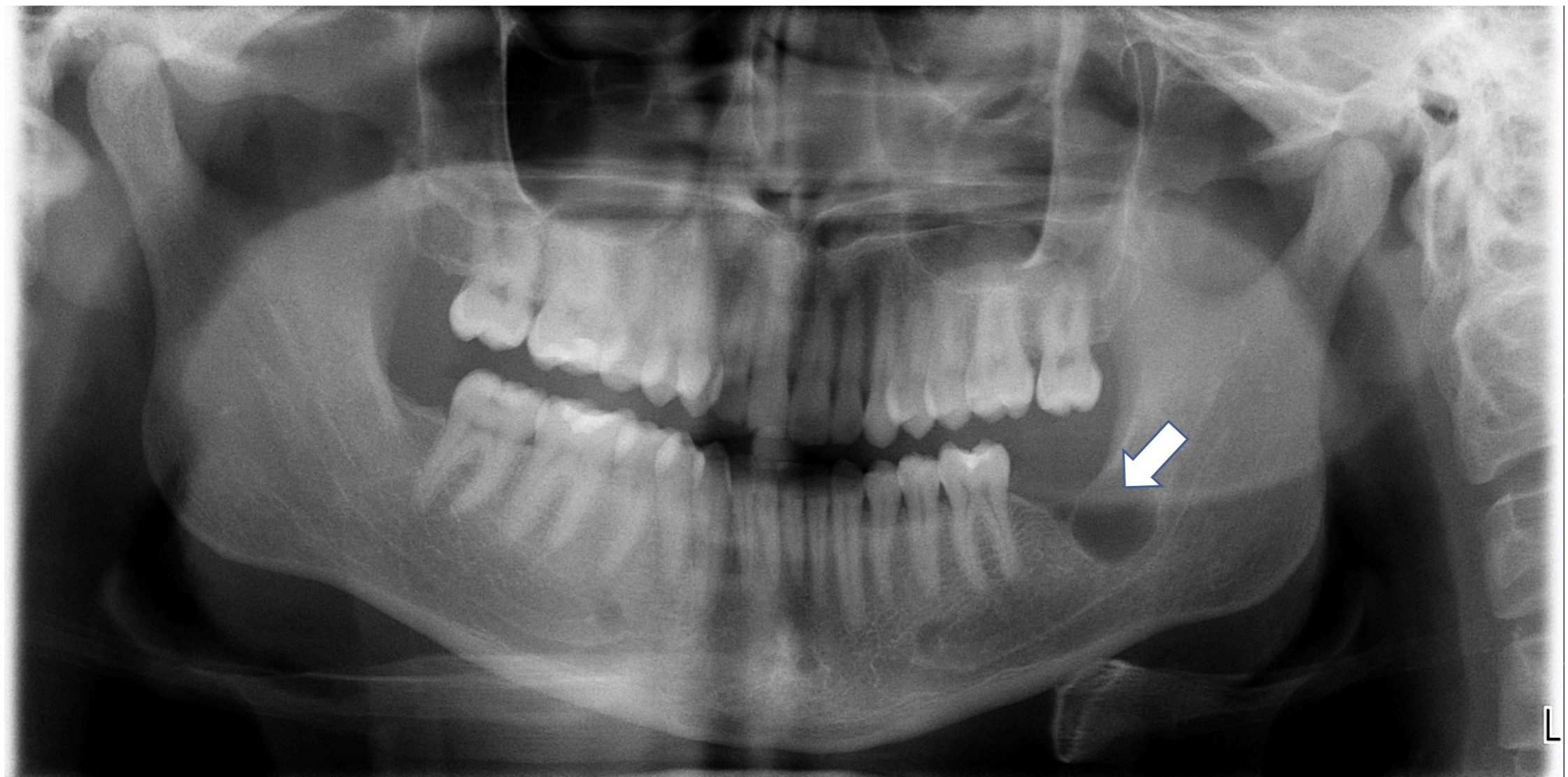


Odontogenic tumor/KCOT

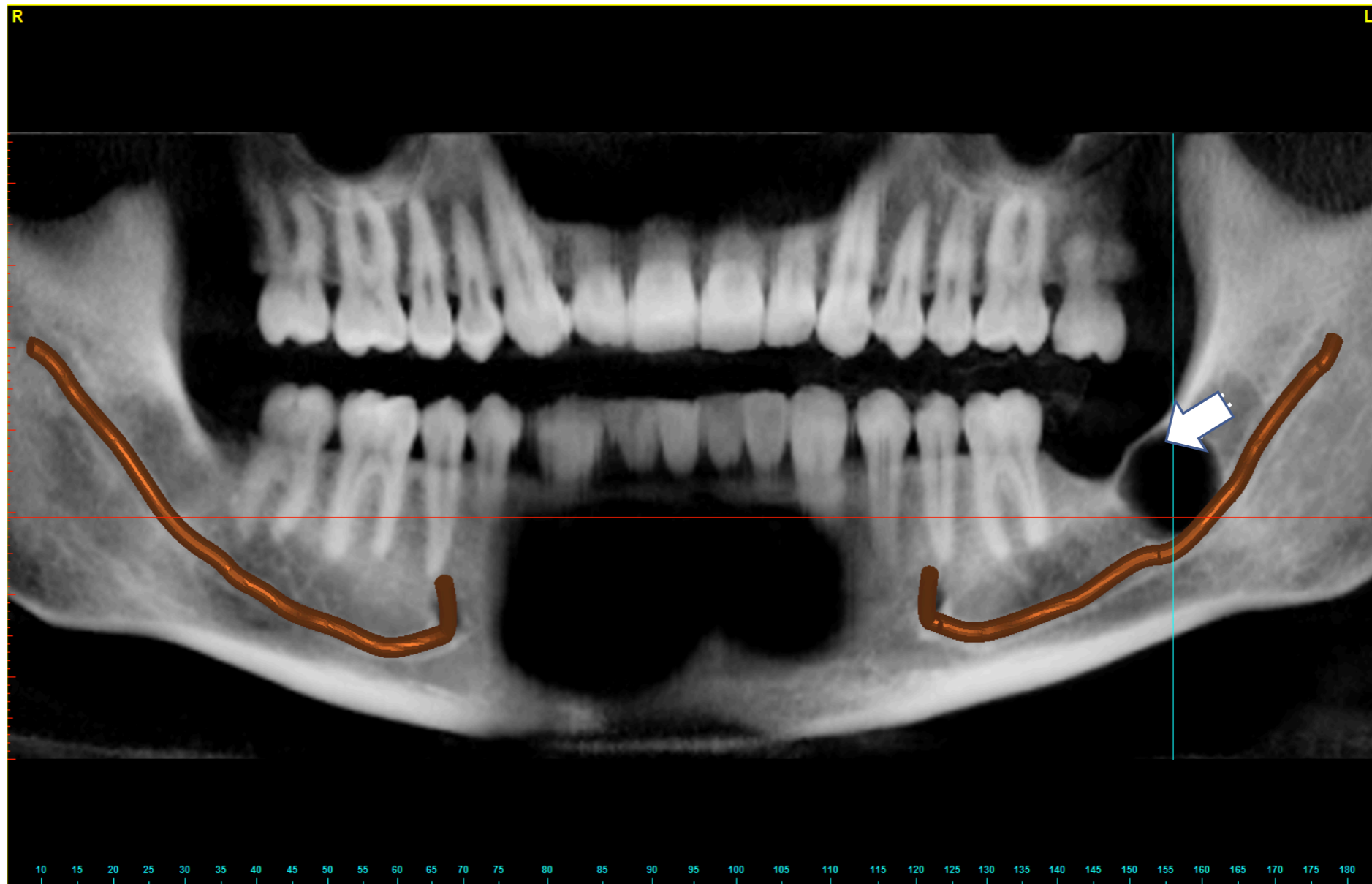


A 27 year-old patient was referred by his general dentist for evaluation and treatment of a lesion of the left mandible. He had undergone removal of his asymptomatic “wisdom teeth” with another dentist seven years previously. The panoramic radiograph revealed a unilocular radiolucency consistent with a large residual cyst. However, clinical examination revealed bony expansion suggestive of a more aggressive process. A Cone Beam CT scan showed erosion through the buccal and lingual plates. Surgical excision of the lesion combined with aggressive manual and rotary curettage was followed by application of Carnoy’s solution. Pathologic diagnosis revealed a Keratocystic Odontogenic Tumor (KCOT) of the left mandible.

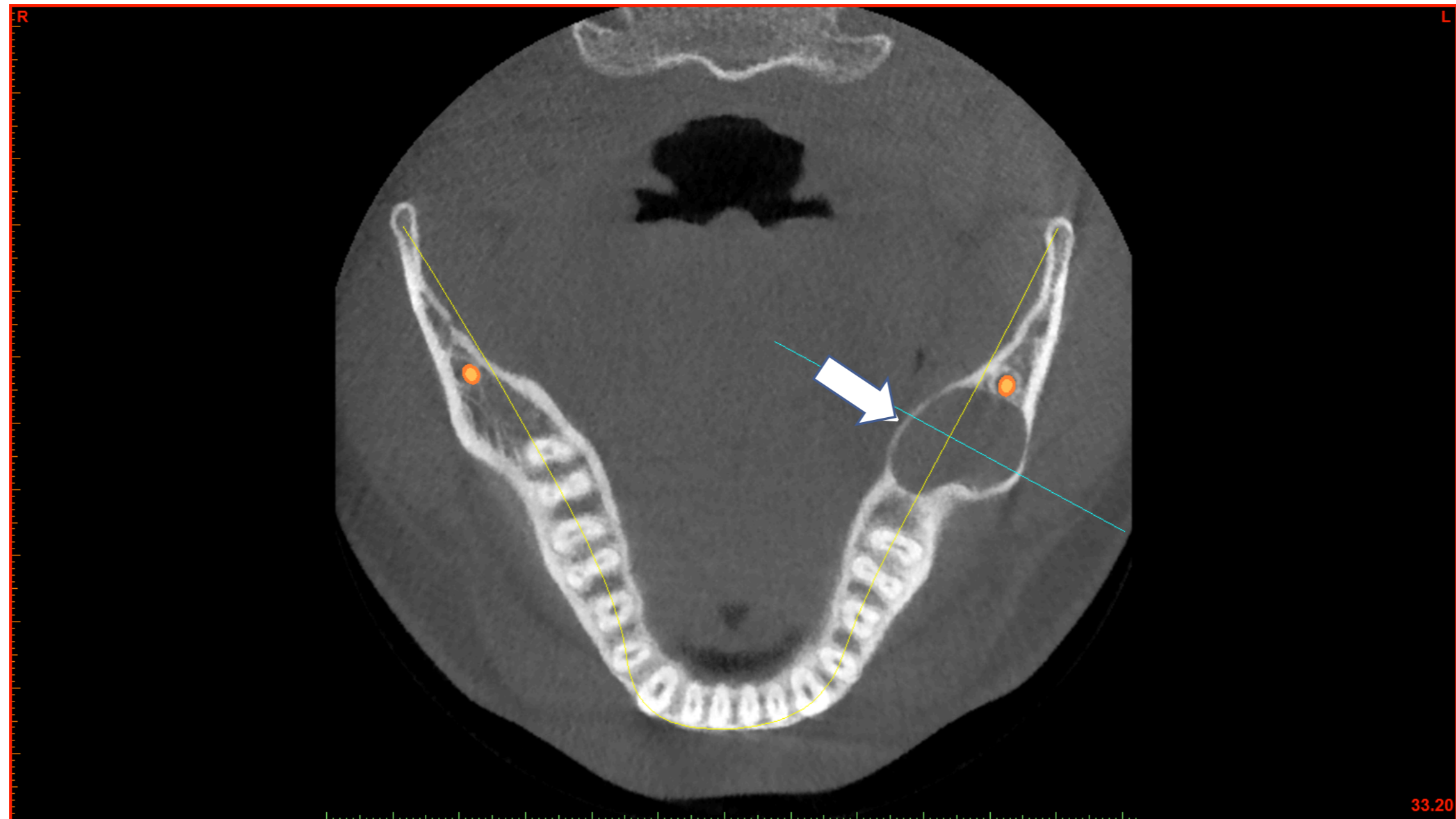
Panoramic radiograph showing lesion of left mandible



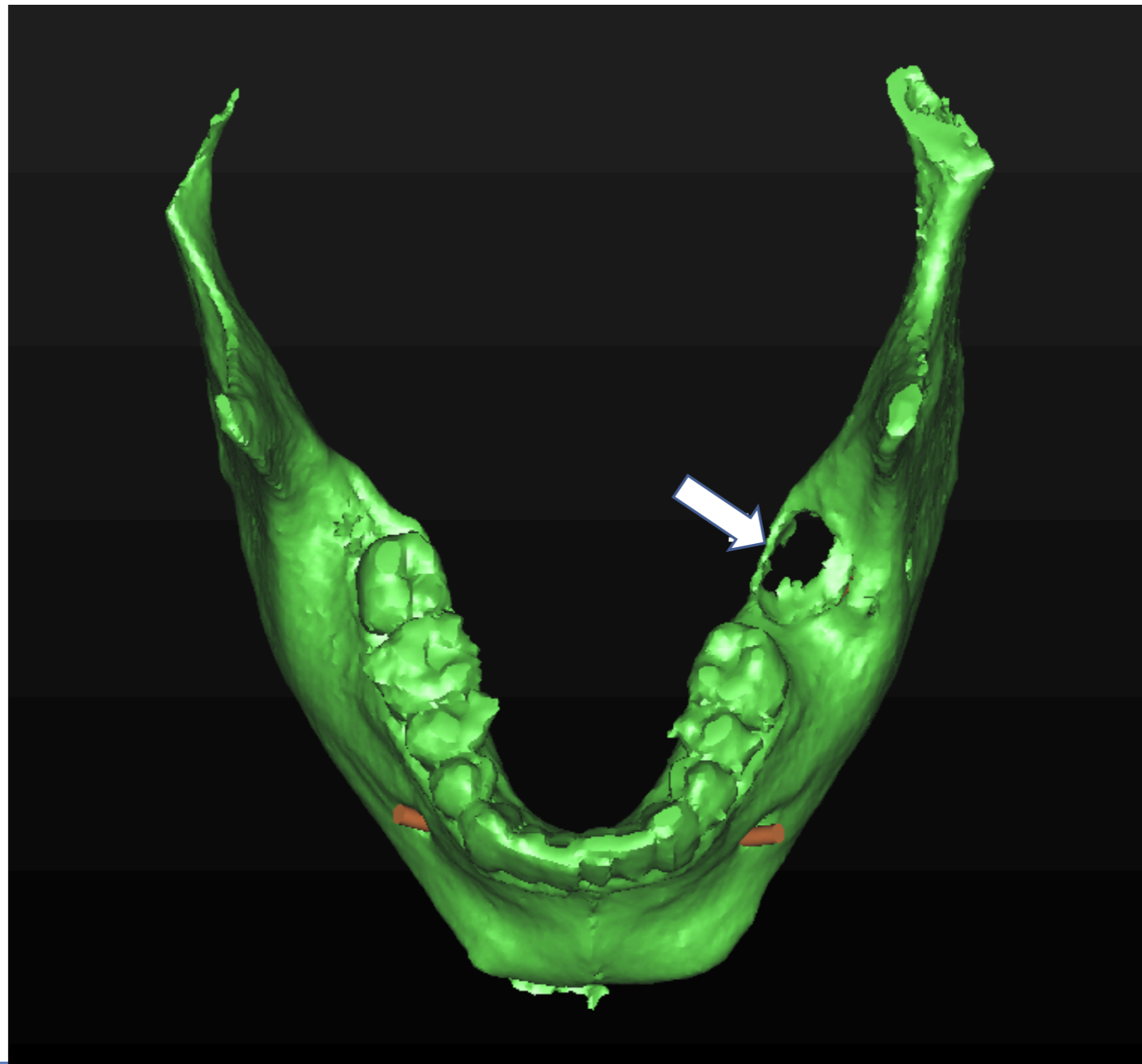
Cone beam CT in panoramic view showing KCOT of left mandible



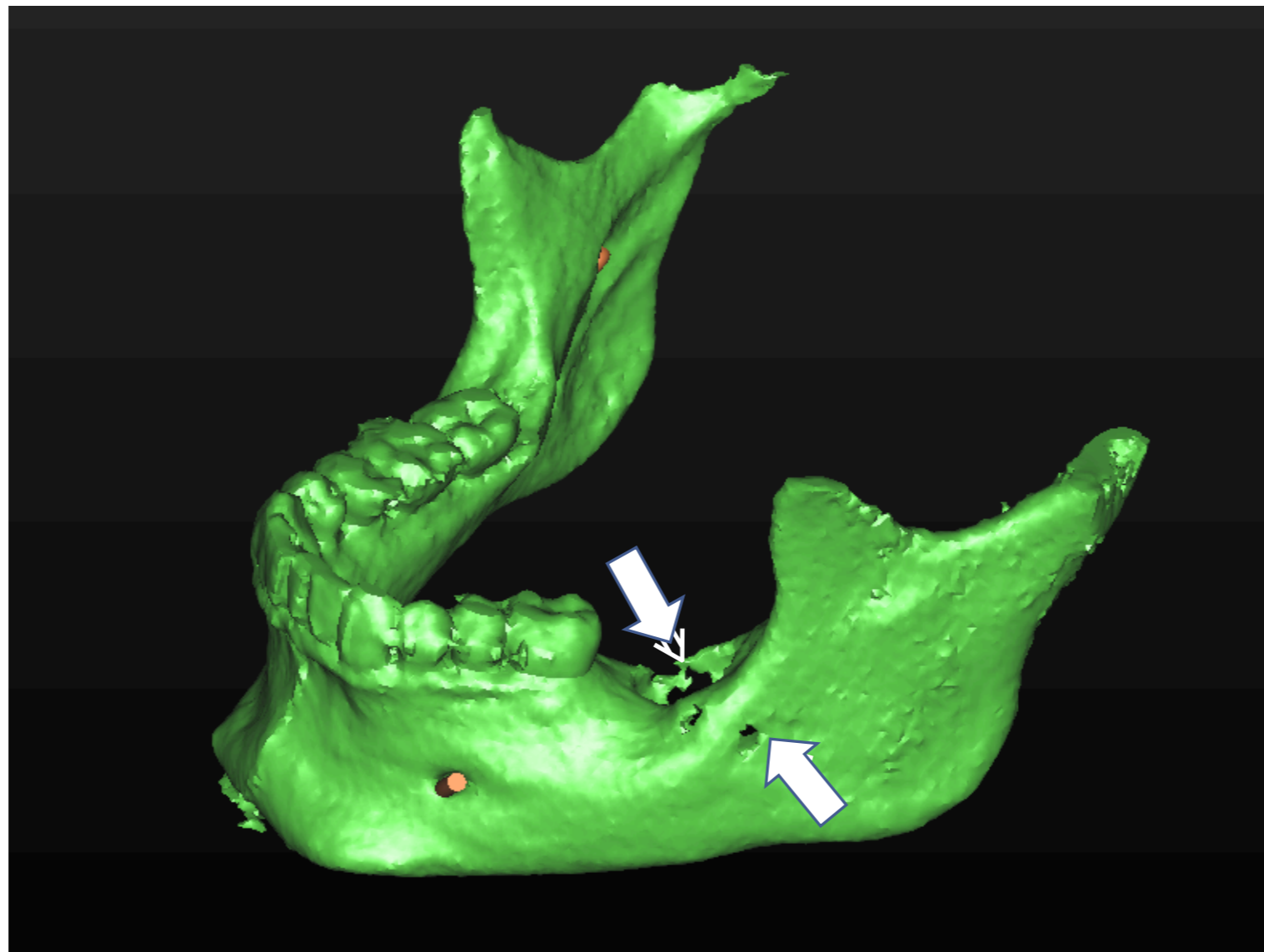
Cone beam CT in coronal view showing KCOT of left mandible



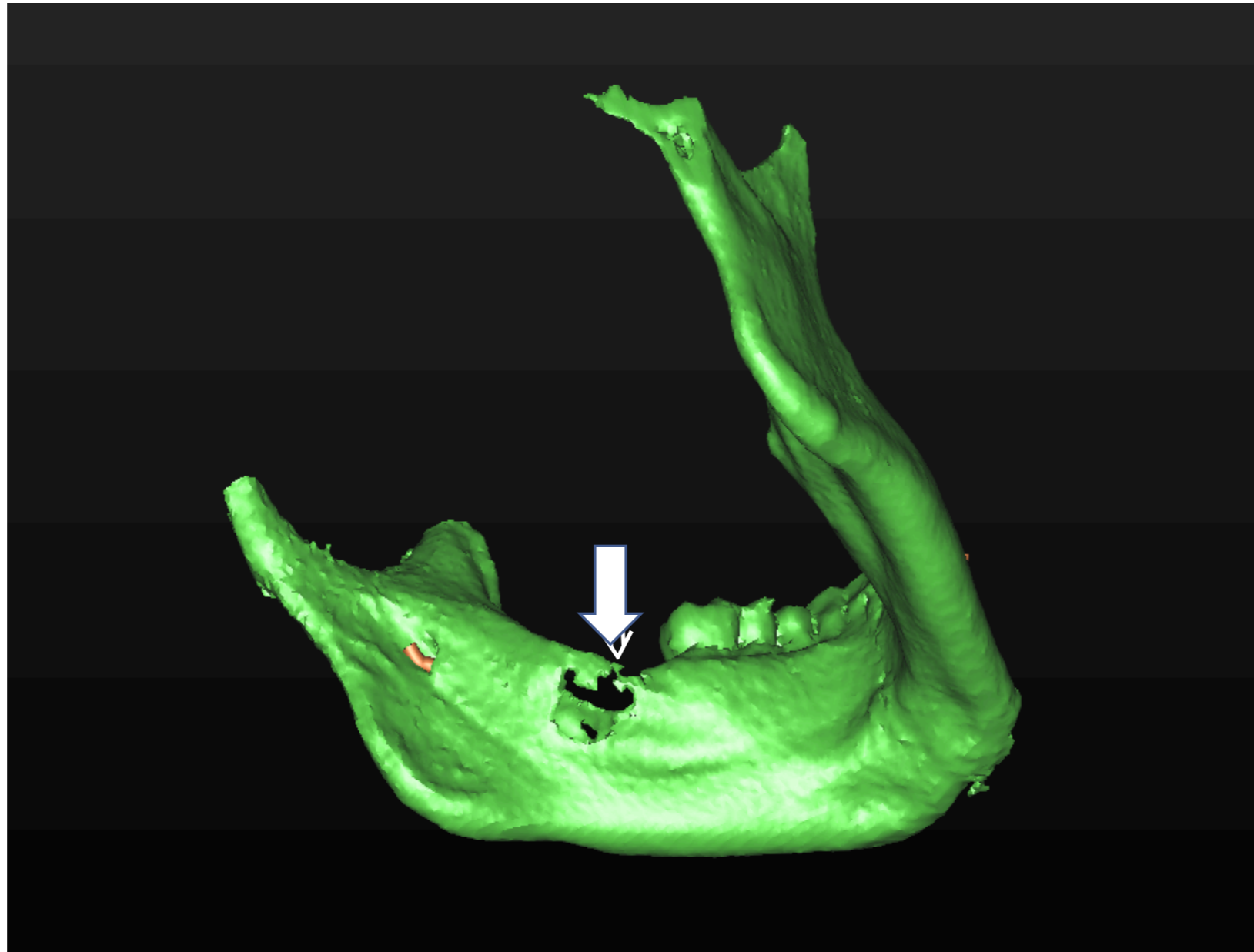
Cone beam CT in topographical 3D view showing KCOT of left mandible



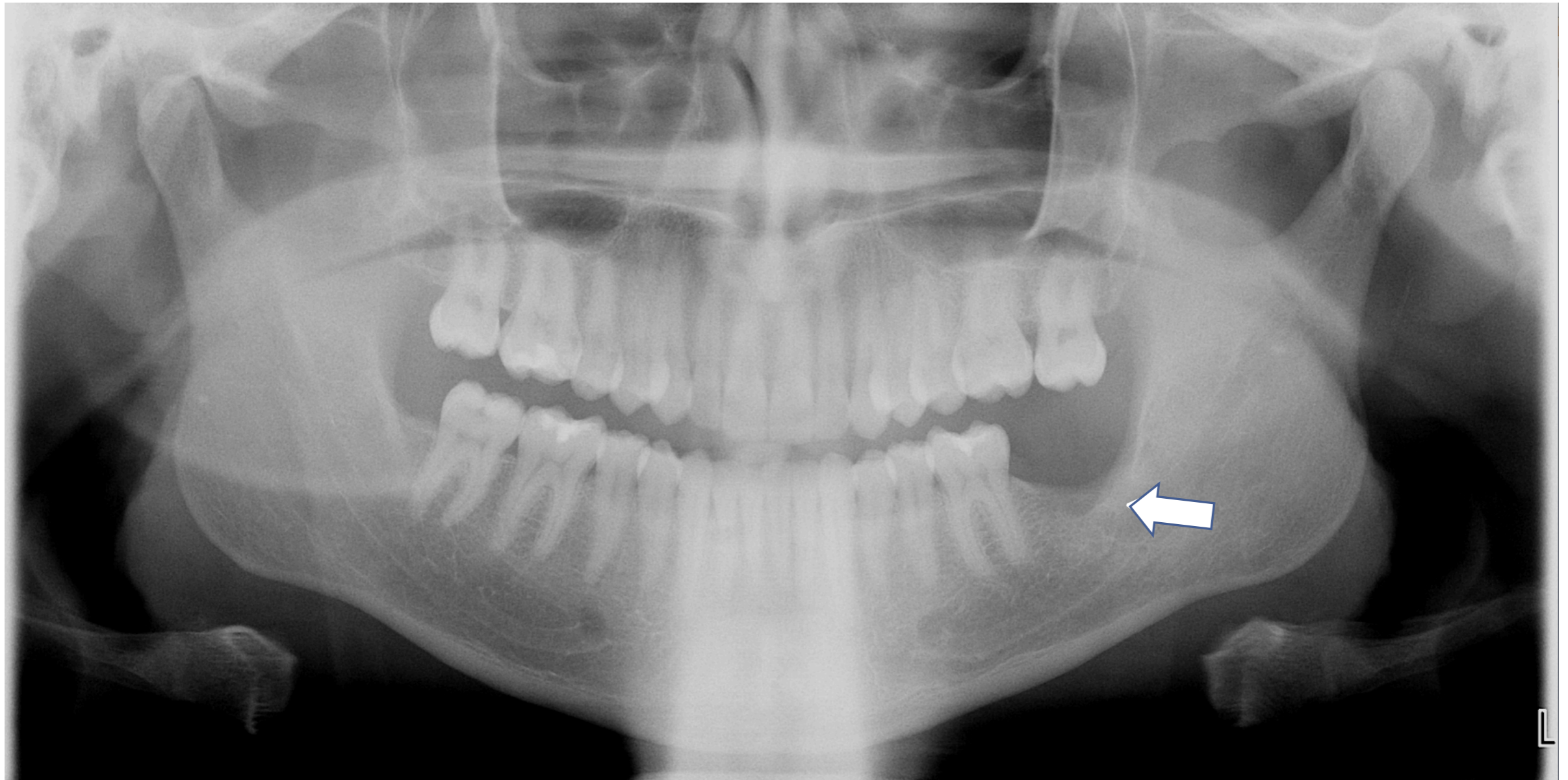
Cone beam CT in topographical 3D view showing KCOT of left mandible



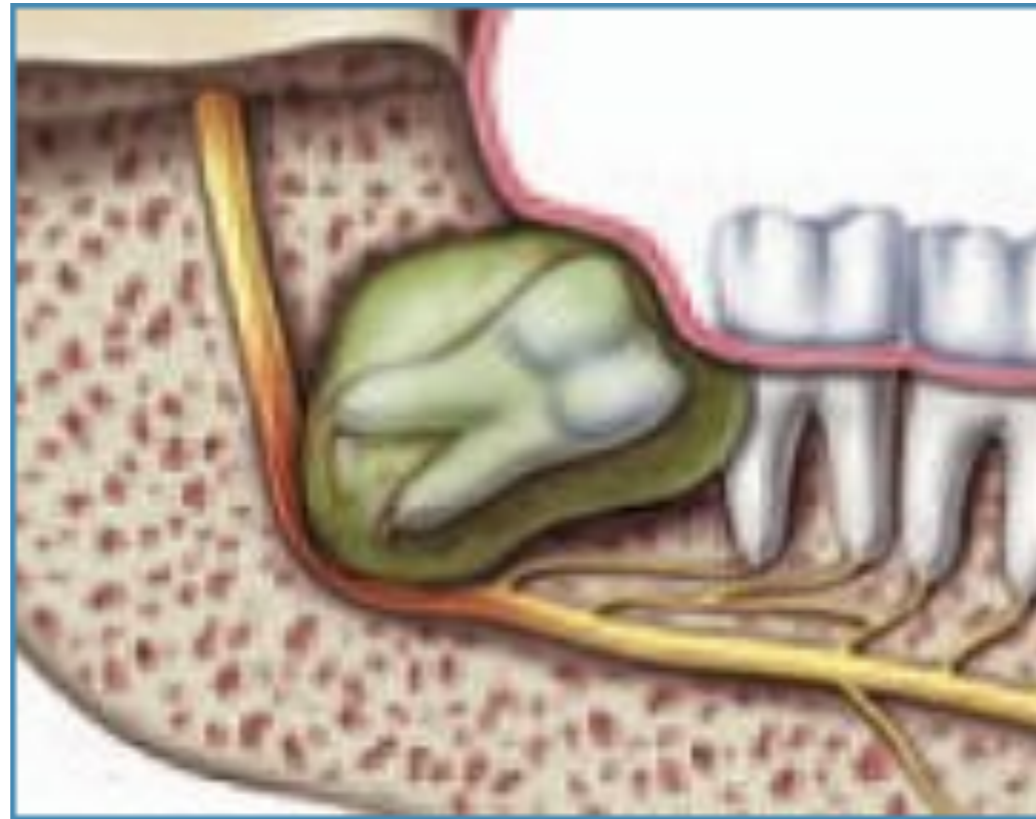Cone beam CT in topographical 3D view showing KCOT of left mandible



One-year postoperative panoramic radiograph of mandible shows no recurrence following KCOT removal

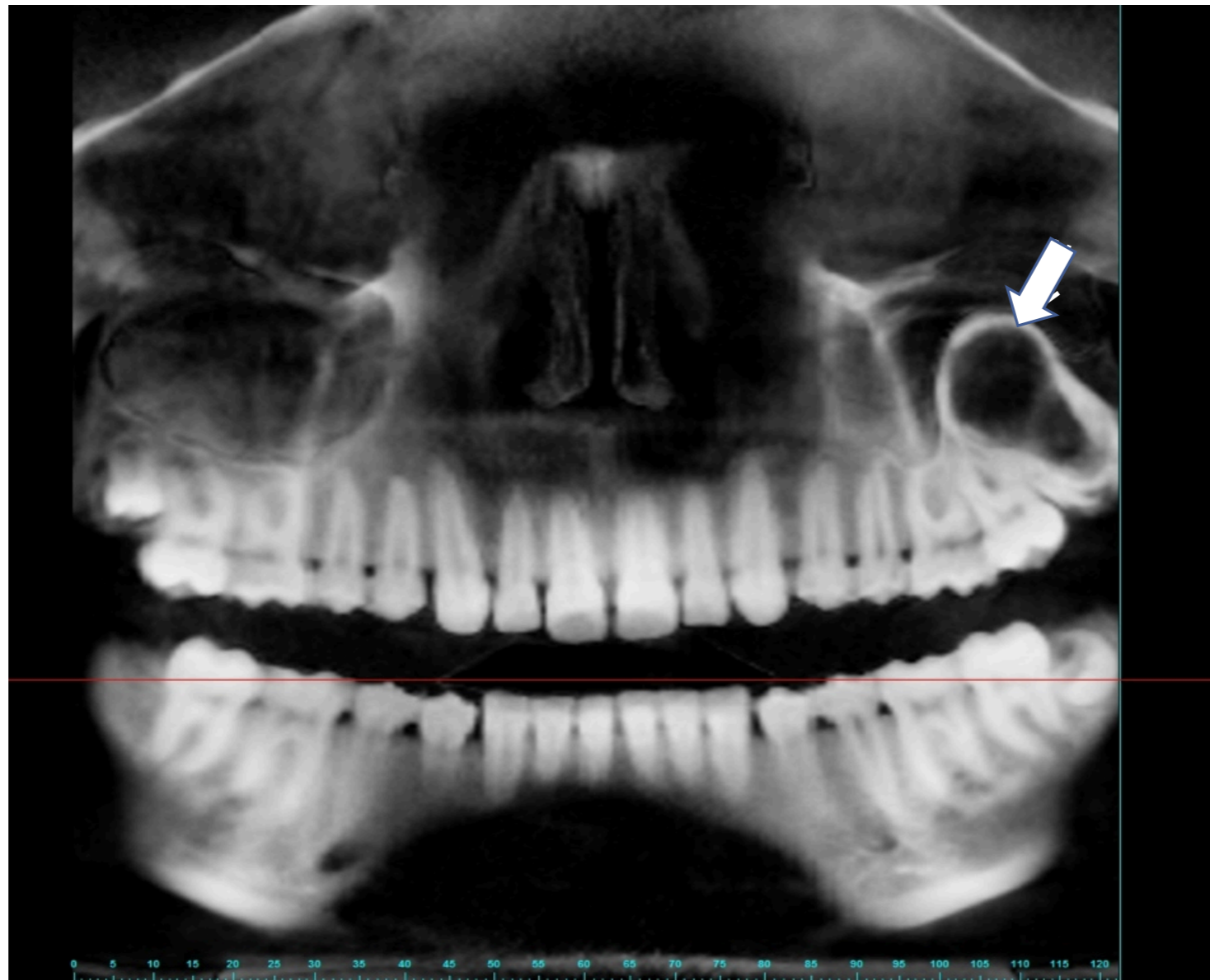


Odontogenic tumor

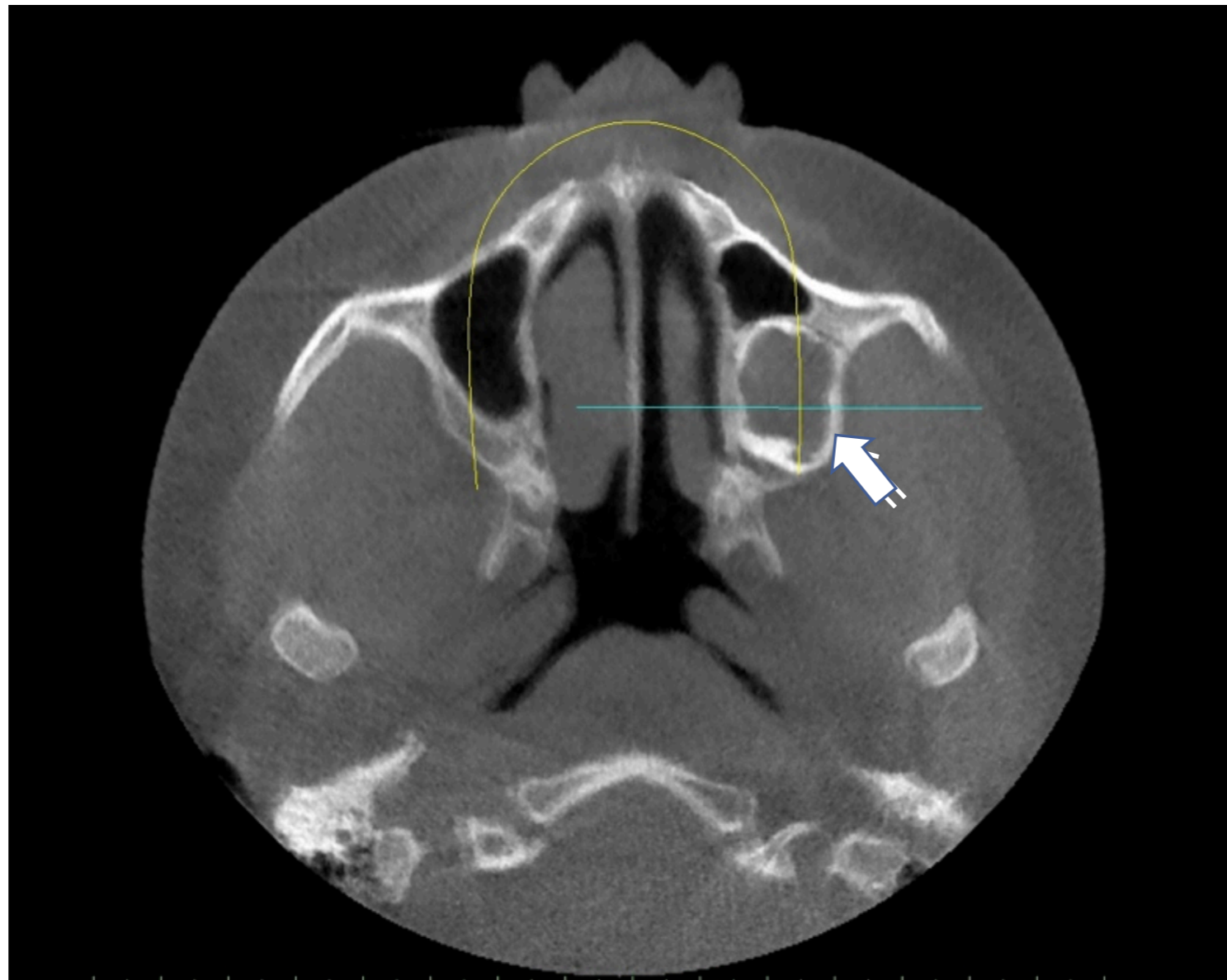


A completely asymptomatic 17 year-old patient was referred by her orthodontist for removal of her third molar teeth and evaluation of a mixed radiopacity/radiolucency of her left posterior maxilla (odontoma with unicystic ameloblastoma).

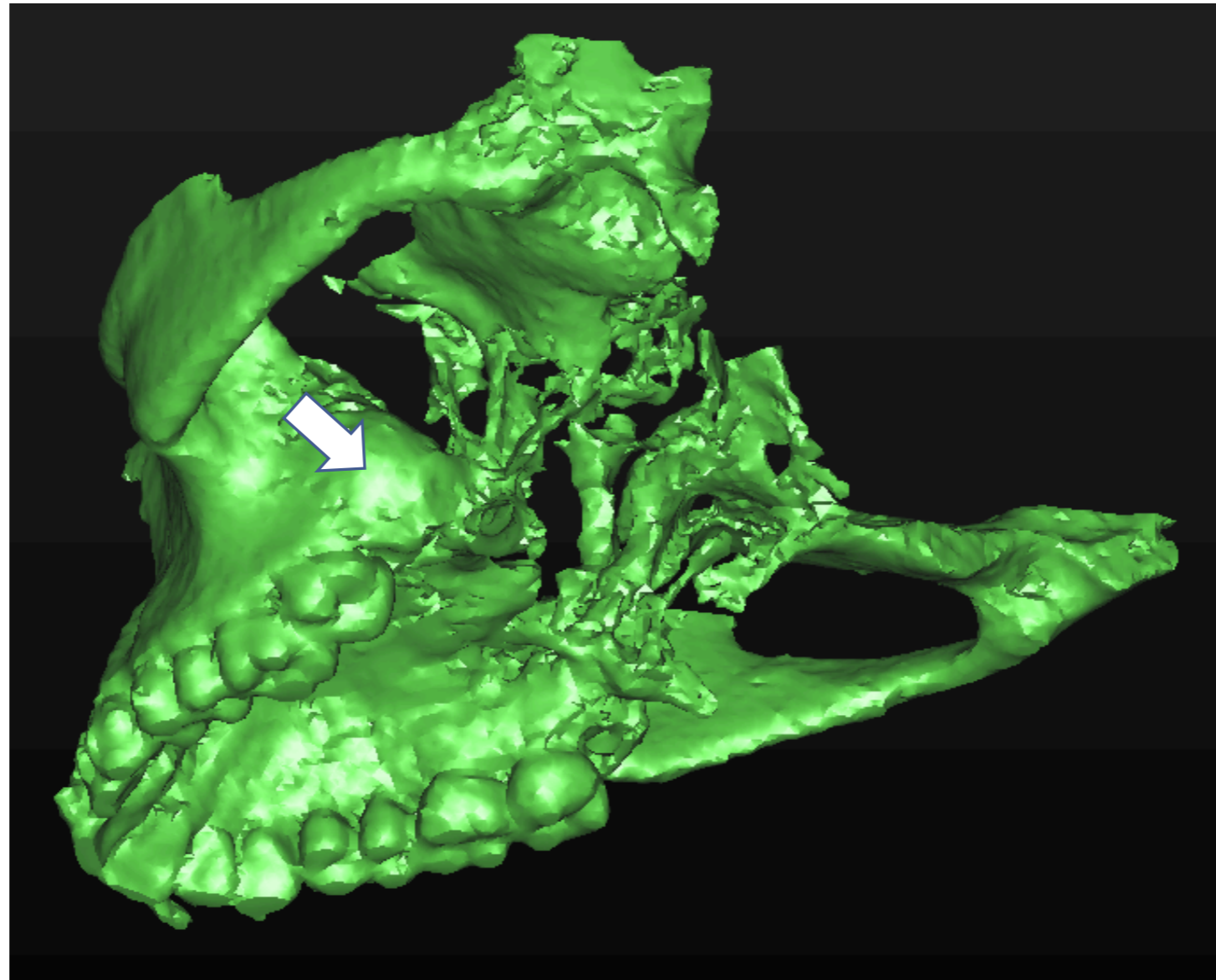
Cone beam CT scan of odontoma and ameloblastoma of left maxilla in panoramic view



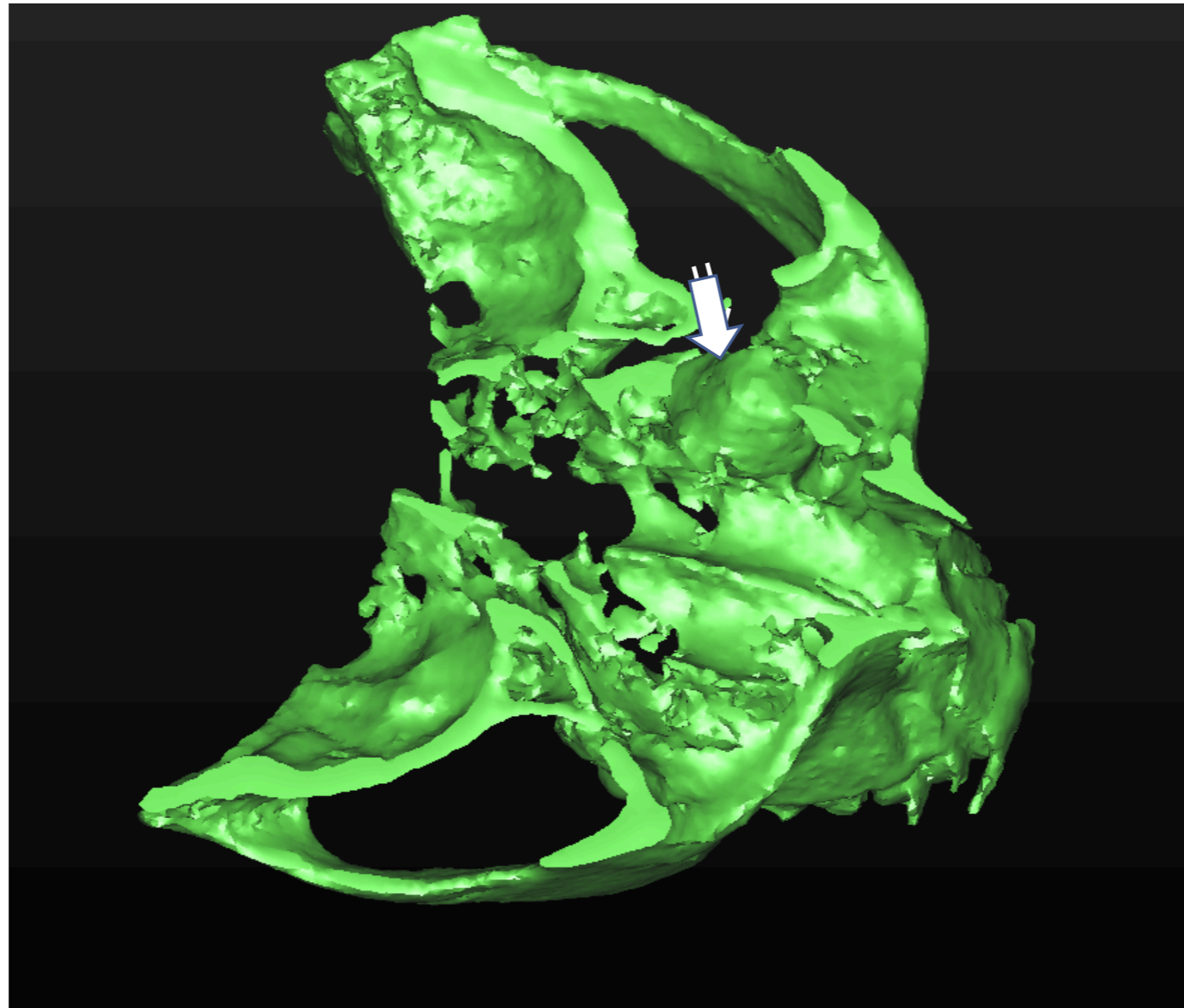
Cone beam CT scan of odontoma and ameloblastoma of left maxilla in coronal view



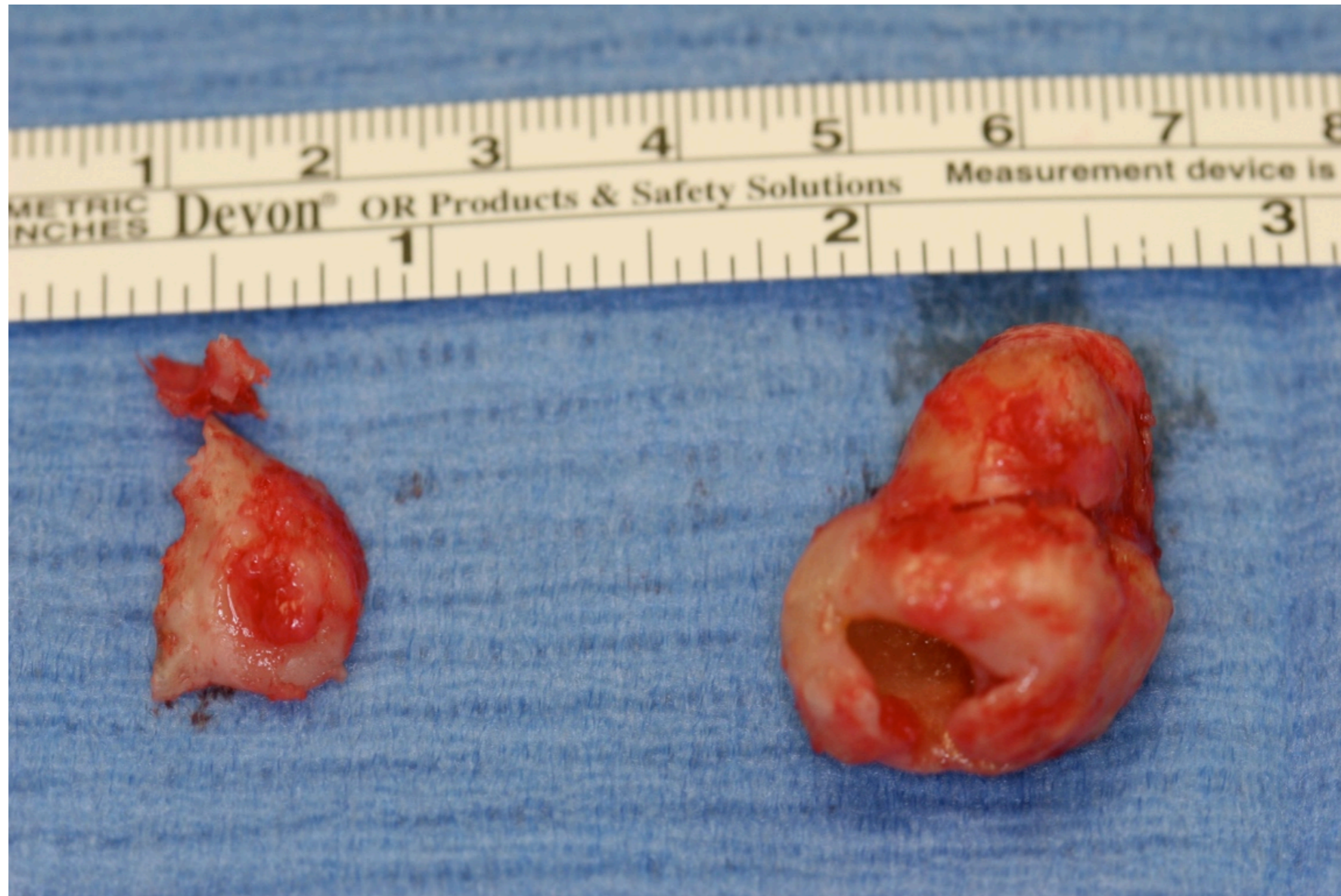Cone beam CT scan of odontoma and ameloblastoma of left maxilla 3D view from below



Cone beam CT scan of odontoma and ameloblastoma of left maxilla 3D view from above



Odontoma with unicystic ameloblastoma



For more information, please see the [AAOMS Advocacy White Paper on Evidence-Based Third Molar Surgery](#)



Saving Faces | Changing Lives®